

Compensative Review Approach on Glaucoma Detection Techniques

Vibhuti Patel¹, Donika Chaudhari²

Assistant Professor, Department of Electronics & communication Engg, Parul University, Vadodara, Gujarat, India¹

Lecturer, Department of Electronics & communication Engg, Parul University, Vadodara, Gujarat, India²

ABSTRACT: There are several papers available on different types for glaucoma detection. Here we are trying to understand possible some techniques and try to represent compensative approach on different detection techniques such as Funduscopy Images, Angio- Optical Coherence Tomography (OCT) Images, Retinal Fundus Images, Colour Fundus Images (CFI). Paper based on compensative review of different glaucoma detection techniques is presented in this paper. The paper also discusses various structural features that are related to CFI and OCT images respectively for automated glaucoma detection.

KEYWORDS: Glaucoma; Funduscopy Image; Optical Coherence Tomography; veins segmentation, Feature extraction; Cup-to-disk ratio(CDR); Image Processing.

I. INTRODUCTION

Glaucoma is an eye infection that steadily takes your vision. Ordinarily, glaucoma has no side effects in its beginning periods. Without legitimate treatment, glaucoma can prompt visual impairment. Fortunately with ordinary eye tests, early identification, and treatment, you can safeguard your sight. This guide will give you a total prologue to the realities about glaucoma.

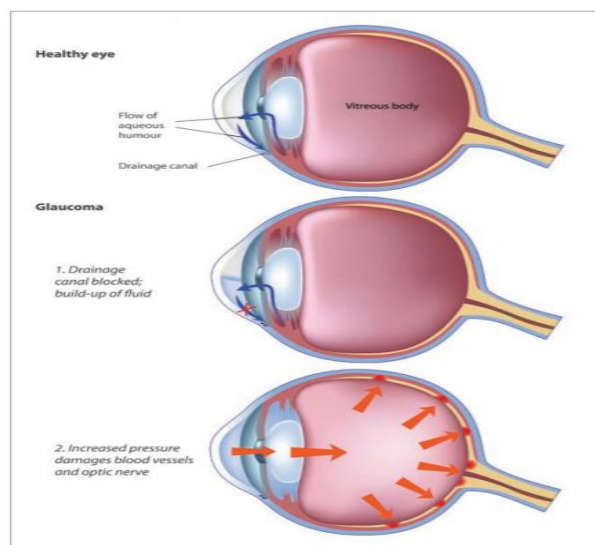


Fig.1 Development of Glaucoma

International Journal of Innovative Research in Science, Engineering and Technology

(A High Impact Factor, Monthly, Peer Reviewed Journal)

Visit: www.ijirset.com

Vol. 8, Issue 12, December 2019

The internal pressure of the eye (intraocular weight or IOP) is reliant on the harmony among creation and waste of watery liquid in the eye. On the off chance that your eye's waste framework is working appropriately, at that point liquid can deplete uninhibitedly out what's more, avoid a development. Similarly, if your eye's liquid framework is working appropriately, at that point the perfect measure of liquid can be delivered. Your IOP can shift during the day, however typically remains inside a reasonable range.

II. METHODOLOGY

A. Picture Preprocessing The human visual framework doesn't see the world in a similar way as advanced indicator; henceforth we have to change over the picture into computerized picture, its only the picture preparing. Here we are improving the difference of a picture for further procedure. We are likewise changing over the picture into dark scale picture.

B. Division of optic plate From the fundus pictures, the optic circle is sectioned. For the division of optic plate we contrast the fundus picture and the limit estimation of '0' while an edge estimation of our item pixel is '1'. After the correlation we get the optic circle limit from fundus picture. In this paper, we are restricting the optic circle limit by examination technique. By utilizing edge discovery we restrict the optic circle.

C. Smoothing of optic plate After doing the division and edge recognition of optic circle, we didn't get the limit of optic circle as wanted. Consequently we are utilizing the circle fitting calculation for limit location.

D. Division of optic cup After finishing the restriction of optic circle limit, optic cup limitation is additionally obligatory. To confine the optic cup limit we utilize the division strategy same as utilized for optic plate division. The extraction of the cup limit we contrast the again optic plate and the clear dark shading picture of a similar size of the picture. From contrasting this we get the optic cup limit.

E. Smoothing of optic cup After the confinement of cup limit, to get the limit as wanted, we use oval fitting calculation. After the smoothing of cup and circle limit we plot the oval utilizing Cartesian organize framework. We likewise discover the cup breadth and circle width utilizing Cartesians technique. The CDR is determined utilizing the optic dis and cup measurement.

F. Cup-to-plate ratio(CDR) As now we are with the circle and cup distance across, presently the following stage is to quantify the cup-to-circle proportion (CDR). Fig 3 shows the typical computation of the CDR. The optic cup locale and optic plate area for typical eye is appeared in fig.2. Prior we restrict the circle and cup limits, after that utilizing Cartesians framework we discover the distance across, tallness focus, and width focus, level and vertical focus. $CDR = \frac{\text{Cup distance across}}{\text{Disk breadth}}$

At the point when the proportion of cup-to-plate is more than 0.3, at that point we can say that patient have the glaucoma sickness. Typical eye has the CDR is under 0.3. We are looking at the CDR, in the event that it's more noteworthy than 0.3, at that point its glaucoma eye generally ordinary eye, which appeared in yield GUI result.

International Journal of Innovative Research in Science, Engineering and Technology

(A High Impact Factor, Monthly, Peer Reviewed Journal)

Visit: www.ijirset.com

Vol. 8, Issue 12, December 2019

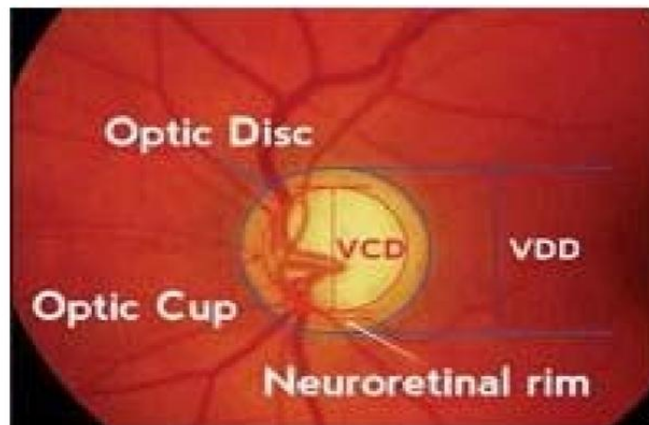


Fig.2 Measuring cup and Disc Ratio

III. DETECTION USING FUNDUS IMAGE

The retinal fundus image is used to measure the thickness of the retinal nerve layer (RNFL) to diagnose glaucoma. It is one of the non-invasive techniques most used by ophthalmologists. Its major advantage is that images can be taken easily for either healthy and nonhealthy retinas, it is also portable and not difficult to use for any health professional, especially in screening campaigns among population without access to health care services.

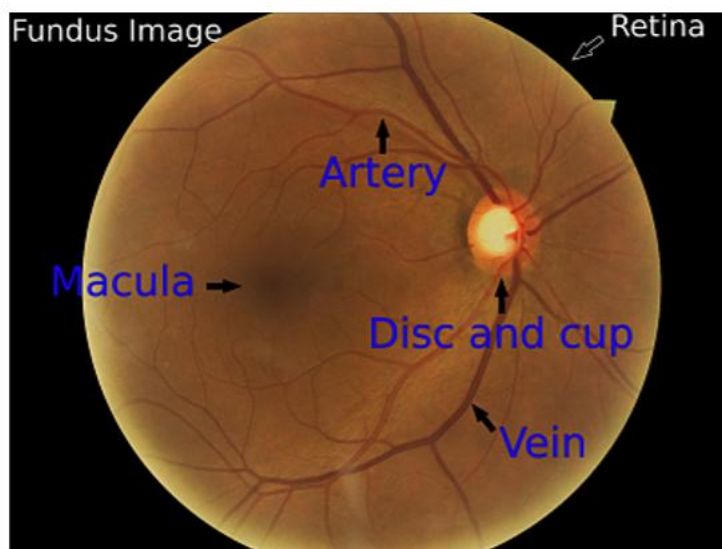


Fig.3 Fundus image and important parts of the eye

The thickness of the RNFL is calculated by measuring the proportion among the size of the optic nerve (named disc) and the size of the excavation inside the optic nerve produced by the increasing eye's pressure (named cup). This parameter is known as the Cup-to-Disc ratio (CDR). Several works has been done for automatic glaucoma detection based on colour fundus images, where the main difficulty is to provide an accurate estimation of the CDR. Anorectal proposes a method for disc segmentation using edges detection. This method has problems if the eye has peripapillary

International Journal of Innovative Research in Science, Engineering and Technology

(A High Impact Factor, Monthly, Peer Reviewed Journal)

Visit: www.ijirset.com

Vol. 8, Issue 12, December 2019

atrophy which is a disease that alternates the edges of the disc. For segmenting the cup it uses as threshold one third of the highest grayscale intensity, however, the distance between the disc pixels and the cup pixels is not always the same, which makes difficult the segmentation among images taken from different persons. Another problem is to detect the cup edges when it is starting to grow in the early stages of the disease.

IV. DETECTION USING Angio-OCT IMAGES

OCT based angiography (OCTA) is another imaging modality providing angio flow profiles at various layers of the retina. It is based on a rapid OCT scanning of the eye at the same location in the retina, over a period of time, to search for changes in the scan. All the structures in the retina are static except for the blood flow through vasculature or by movement of the eye itself. Mapping these territories of blood flow is finished utilizing the Split-Spectrum Amplitude-Decorrelation Angiography calculation [10] to infer exceptionally point by point maps of the vasculature in a non-invasive way rather than fluorescein angiography. Specifically, notwithstanding basic data about the retinal layers, OCTA likewise gives angio flow (enface or top view) pictures which catch angiographic data at various layers to be specific, the superficial fine plexus, profound narrow plexus, external retina and choriocapillaris zone which help a definite investigation of the slim system. We propose a system for glaucoma appraisal from OCTA pictures. Some portion of the objective in building up this system is to pick up bits of knowledge into the relationship between's slim drop out at different layers and RNFL thickness in foreseeing glaucoma. Thus, the frame work is based on the RNFL thickness and slim thickness around ONH. The previous is evaluated from the OCTA cuts while the last is gotten from the angio flow (enface) pictures. The proposed technique has been approved against information gathered from 49 typical and 18 glaucomatous eyes.

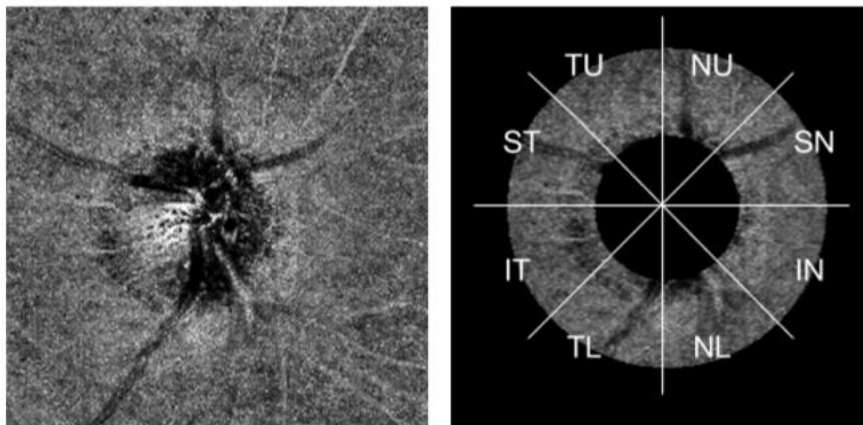


Fig. 4 Choroid Disc Angio flow image (left) and Eight sectors of ROI (right) for a Right Eye.

V. CONCLUSION AND FUTURE PLAN

The nearness of the cup in the plate is a solid pointer of glaucoma, a strategy to distinguish glaucoma was displayed here by appropriately identifying the area of the cup. The plate division was finished by thresholding, the vessel division was finished utilizing edge discovery, and for the cup division it was displayed a technique that uses the vessels and the cup powers. Both method was good but in oct accuracy is good for detection.s

Future work worries to acquire a greater dataset of fundus pictures to make a more profound trial of the calculation. The vessels division requires an improvement because of some bombs in various pictures and lingering commotion after the division. The utilization of convolutional neural systems is a piece of things to come work to improve the classification.

International Journal of Innovative Research in Science, Engineering and Technology

(A High Impact Factor, Monthly, Peer Reviewed Journal)

Visit: www.ijirset.com

Vol. 8, Issue 12, December 2019

REFERENCES

1. Automatic Glaucoma Detection by Using Fundus Images, 2016 IEEE, Atheesan S., Yashothara S. Department of Information Technology University of Moratuwa Katubedda, Sri Lanka.
2. Automatic Glaucoma Assessment from Angio-OCT Images, 2016 IEEE , Karthik Gopinath? Jayanthi Sivaswamy Tarannum Mansoori , CVIT, IIIT-Hyderabad, India †Anand eye institute, Hyderabad, India.
3. Detection of Glaucoma Using Retinal Fundus Images, Hafsa Ahmad*, Abubakar Yamin**, Aqsa Shakeel*, Syed Omer Gillani*, Umer Ansari*, 2014 International Conference on Robotics and Emerging Allied Technologies in Engineering (iCREATE) Islamabad, Pakistan, April 22-24, 2014.
4. Glaucoma Detection from Fundus Images Using MATLAB GUI , 2017 , Shwetali M. Nikam Dept. of Instrumentation and Control College of Engineering, Pune Pune, India shwetalinikam.5@gmail.com.
5. GLAUCOMADETECTIONUSINGFUNDUSIMAGESOFTHEEYE ,2019 . Juan Carrillo*, Lola Bautista*, Jorge Villamizar*†, Juan Rueda‡, Mary Sanchez‡ and Daniela rueda‡ *School of Computer Systems Engineering and Informatics, and School of Mathematics Universidad Industrial de Santander, Bucaramanga, Colombia Email: juan.carrillo3@correo.uis.edu.co,lxbautis@uis.edu.co
6. Review of Automated Glaucoma Detection Techniques , IEEE WiSPNET 2016 conference , Sharanagouda Nawaldgi Dept. of Electronics & Communication Engineering APPA Institute of Engineering & Technology Kalaburagi, Karnataka, India. sharan_yn@yahoo.co.in.
7. Retinal fundus image for glaucoma detection: A review and study. Journal of Intelligent Systems, 28(1):43– 56, 2017 , S. S. Kanse and D. M. Yadav.
8. Application of vascular bundle displacement in the optic disc for glaucoma detection using fundus images. Computers in biology and medicine, 47:27–35, 2014, Jos'e Abel De La Fuente-Arriaga, Edgardo M Felipe-River'on, and Eduardo Gardu'no-Calder.
9. S.M. Nikam and C.Y. Patil. Glaucoma detection from fundus images using matlab gui. In 2017 3rd International Conference on Advances in Computing, Communication & Automation (ICACCA)(Fall), pages 1–4, 2017.
10. Jyotiprava Dash and Nilamani Bhoi. A thresholding based technique to extract retinal blood vessels from fundus images. Future Computing and Informatics Journal, 2(2):103–109, 2017.
11. J.C. Rueda, D.P. Lesmes, J. C. Parra, R. Urrea, J.J. Rey, L.A. Rodriguez, C.A. Wong, and V. Galvis. Valores de paquimetr'ia en personas sanas y con glaucoma en una poblaci'on Colombiana. MedUNAB, 10(2):81–85, 2007.