

Robust Blood Vessel Segmentation for Retinal Images

Dr. Savitha¹, Geethanjali G²

Professor, Department of Computer Science & Engineering, BNM Institute of Technology, Bengaluru, India¹

P.G. Student, Department of Computer Science & Engineering, BNM Institute of Technology, Bengaluru, India²

ABSTRACT: The human eye is a very important organ of site. It may be affected by many disorders like glaucoma, cataract, age related macular degeneration (ARMD) and diabetic retinopathy (DR). Blood vessel segmentation of fundus images has obtained during last few years since it detects the early detection of eye diseases. The blood vessel segmentation is helps to provide a method for to detect glaucoma and diabetic retinopathy. In this proposed method there are two methods are used based on eye pass filtering and morphological operation is introduced. The advantage of method is used to calculating the area of blood vessels in each of the four quadrants of the eye glaucoma and DR can be detected in less complexity in simplest form. DR is one of the most common eye disease that leading to cause blindness among people over 40 and above DR is damage to the retina, it is the part at the back of the eye. It can also affect people with diabetes is DR. Early detection of DR is essential to avoid vision loss. Diabetic patients requires early detection and continuous monitoring of patient. Some of the physical tests like visual acuity test, pupil dilation & optical coherence tomography can be used to detect the disease. Detection of DR disease proves to be more cost effective and time consuming. Using machine learning applications & algorithms to classifying the features extracted from output. Different retinal image will give more accuracy for prediction of the disease. Presence of DR is performed using random forest and support vector machine. Bothe DR & glaucoma can be detected with less complexity in a simpler manner.

KEYWORDS: Disease detection, Blood Vessel Segmentation, Fundus Image, ISNT Ratio, Morphological operations.

I. INTRODUCTION

Medical database which contains information about various disease. Giving helpful information and logical dynamic for the distinguishing and treatment of sickness from the database. Medical data in medicine can deal with this. It can also develop the management level of hospital information and improves the telemedicine & community medicine. Diabetes is an incessant and organ ailment that happens when the pancreas doesn't release enough insulin. Diabetes influences the round framework. Diabetic Retinopathy (DR) is one of the most widely recognized eye malady and a portion of the eye illness are glaucoma, waterfall, Age Related Macular Degeneration (ARMD), and DR. Glaucoma is additionally a one basic eye type malady is cause optic nerve harm. Waterfall is additionally a one kind of ailment that cause visual impairment in the eye individuals over 40.

Diabetic retinopathy disease damages to the retina and is the part at the back of the eye, it can affect people with diabetes is called diabetic retinopathy. It improves a problem in their eyes. The proposed work focuses on detection of glaucoma and DR using machine learning applications. 400 million diabetic individuals are in the hazard for having visual impairment by diabetes, when little veins are harmed inside the retina and light touchy tissue at the rear of the eye, because of this difficult vessels become spill and in that the liquid come out for to upset eye to DR persistent, it structures highlights, for example, small scale aneurysms, hemorrhages, hard exudates, cotton fleece spots or venouscircles.

Diabetic retinopathy is named as Non-Proliferative Diabetic Retinopathy (NPDR) and Proliferative Diabetic Retinopathy (PDR). Contingent upon the nearness of highlights on the retina, the phases of DR can be recognized. In the NPDR stage, the ailment can progress from mellow, moderate to serious stage with different degrees of highlights aside from less development of fresh blood vessels. PDR is the propelled stage where the liquids sent by the retina for sustenance trigger the development of fresh blood vessels.

They develop along the retina and over the outside of the reasonable, vitreous gel that fills within the eye. On the off chance that they release blood, extreme vision misfortune and even visual deficiency can result. As of now, recognizing DR is a tedious and manual procedure that requires a prepared clinician to look at and assess advanced shading fundus photos of the retina. When human per users present their surveys, frequently a one day or multi day later, the deferred outcomes lead to lost development, miscommunication, and postponed treatment. The fundus pixel of the eye is the inside surface of the eye inverse the focal point and incorporates the retina, optic plate, macula, and fovea and back

shaft. The veins in the fundus picture ought to be sectioned and investigated to get a thought of the infection influencing the eye like glaucoma and diabetic retinopathy. Visual deficiency is a developing issue everywhere throughout the world. On the off chance that these maladies can be distinguished before, at that point visual impairment can be forestalled at the most punctual. Here comes the significance of vein division. For the division procedure, most of the part is utilized as the greenchannel.

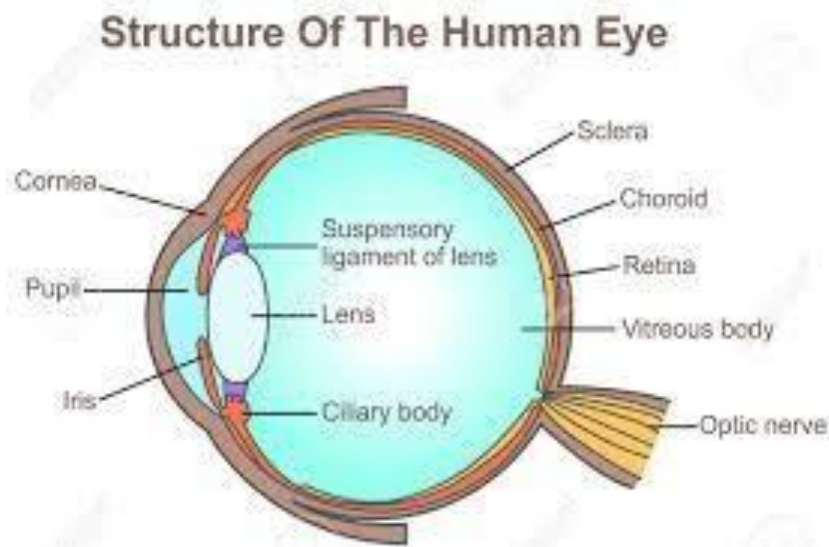


Figure 1.1: The Human Eye Structure.

How the eye works.

Light is centered on the cornea, the spotless surface of the eye, it acts like a camera focal point. The iris of the eye working like a stomach of a camera that control the measures of light coming to at the rear of the eye. The eye's focal point is found straightforwardly behind the student. It further concentrates light, through a procedure called convenience. This focal point encourages the eye to naturally concentrate on close and moving toward objects, similar to a self-adjust camera focal point.

Diabetic Retinopathy.

Diabetic Retinopathy is a diabetes inconveniences that influences eyes and it tends to be appeared in Figure 1.2. It's made harm the retina it is a delicate tissue present near to rear of the eye. At the underlying stage it has no indications it just has mellow eye issues. It influences individuals more than 45. And furthermore, influences the individuals who are experiencing diabetes it obliterates the focal vision of the eye. In the beginning stage the patient doesn't know about this ailment nearness. The wellbeing of the macula confirms that capacity to peruse, perceive faces and everything, drive, and sit in front of the TV, PC and other execution of visual undertaking to find indetail.

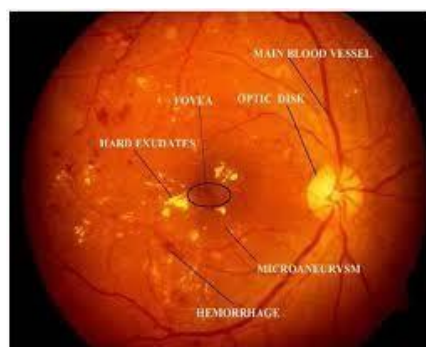


Figure 1.2: Diabetic retinopathy.

Glaucoma

Glaucoma is one type of eye disease the disease cause on people over 50 due to the damage in eye. And it also causes optic nerve damage it can be shown in Figure 1.3. It causes blindness in the eye,

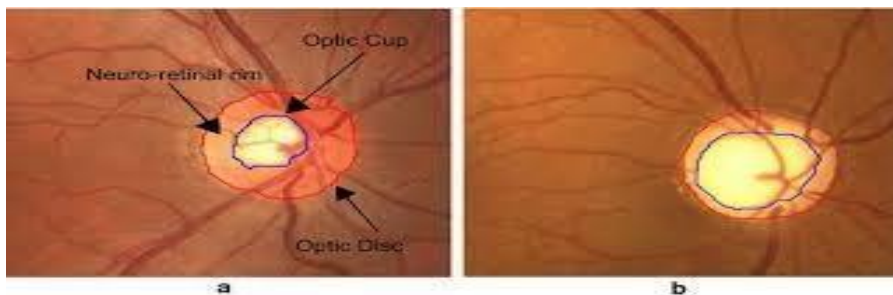


Figure 1.3: Glaucoma

Fundus Image

Fundus pixel of the eye is the inside surface of the eye, inverted to the focal point and it integrate the retina, fovea, optic plate and macula are spoken to in Figure 1.4. A fundus picture of photo of the inside surface of the eye. Fundus pictures are utilized in the finding via prepared clinicians to check for any variations from the norm or any adjustment in the retina.

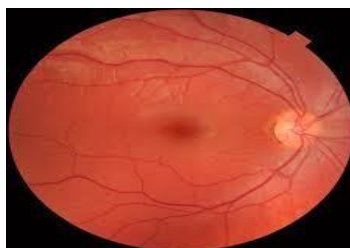


Figure 1.4: Sample of Fundus Image.

Retina is the sensitive layer present near to the rear of the eye. It covers 60 percent of its inside portion surface which is appeared in Figure 1.4. It contains two photosensitive cells called pole and cones in the retina. Retina has a little dimple called fovea, and it is situated atthe focal point of the macula. It contains bigger cone cells. Optic nerve is situated at the rear of the eye. Optic nerve moves the vital information from eye to your mind. The data about the optic circle can be utilized in the seriousness of some ailment, for example, glaucoma. That adjustments in the optic plate can show the present status and movement of a specific sickness. Macula is an oval shape pigmented region adjacent to the focal point of the retina of the natural eye. It partitioned in to fovea. Clinical picture investigation and handling has extraordinary importance in the field of medication. A vessel division in fundus picture investigation could give location and portrayal. Clinical experts need to invest more energy to survey fundus pictures. Driving reason for visual impairment in grown-ups with a deficiency of ophthalmologist and optometrist. Ideal treatment of DR requires early analysis and, in this way, standard eye assessments. It is more diligently to choose to allude or not the patient to the ophthalmologist, DR hazard evaluation is mind bogglng dependent on the nearness of sore and theirdevelopment.

II. RELATED WORK

Karan Bhatia et.al [1] Proposed Diagnosis of Diabetic Retinopathy Using Machine Learning Classification Algorithm. Algorithms related to Machine Learning Techniques about the decision of the pattern of disease can be solved as well. The specific features are withdraw from the output pixel of different retina pixel. The reading of the optic nerve’s diameter made note of. The speed of the dilation and contraction of the pupil of the eye is also taken down. The ease at which the processing is done is very simple. The patients with early symptoms need to be diagnosed as early as possible. Advantages: The intelligent system are proposed with some ideas which is ear and can be understood. Disadvantages: Types of Diabetic Retinopathy cannot be classified using this system.

SnehalDilipKasurde et.al [2] illustrated “An Automated Detection of Proliferative Diabetic Retinopathy”. It is a stage of retinopathy where in the growth of the blood vessels is faster. Also, the blood vessels are not seen to be growing at a normal rate and hence the growth of abnormal blood vessels is seen. The vessel’s first segmentation is converted to a binary image. Separation of the vessel and non-vessel is also practiced. By using the method called feature extraction, the image is windowed into 50 by 50 so that the number of pixels of the vessels can be calculated in each window.

Advantage: New blood vessels can be detected by using the automated system. Bright lesions failure is reduced.

Disadvantage: Non-proliferative diabetic retinopathy can’t be detected using this system.

Mohd. FaziHashim. [3] Proposed Diabetic Retinopathy lesion finding using region based approach. Hard retina, blocked blood vessels, abnormal growth of blood vessels, redness in the eye. The fundus image is identified using region method. This method is used to detect the abnormal region using this proposed method an approach wherein the lesion is observed and removed using structural removal method. This stage is supplanted by distinguishing anomalous locale utilizing district based methodology. Two types of classification is done in this method. SVM & MLP are used 71.94% accuracy is obtained in SVM and 74.53 % accuracy is obtained. The area based methodology can possibly be utilized for the recognition of sore dependent on affectability, explicitness and precision.

Advantage: The benefit of area based methodology is no typical division and expulsion of ordinary structure required.

Disadvantage: This work would not give desired results.

Lama Seoud. [4] Presented Red lesion detection using dynamic features for diabetic retinopathy screening. Programmed telemedicine framework was created for PC helped screening and evaluating of diabetic retinopathy. It primarily relies upon solid identification of retinal sores in fundus pictures. In this novel technique for programmed identification of both microaneurysms and haemorrhages in shading fundus pictures is depicted. The significant commitment is another arrangement of shape highlights called dynamic shape highlights.

It is not required to extract the division of the local fundus image to be grouped. Highlights speaks to the state of advancement during picture flooding and permit to separate among sores and vessel division. Utilizing six information bases the proposed strategy is approved per sore and per picture. The fundus accumulated in the eye can multiply if it isn’t treated in the initial stages.

Advantage: It ends up being strong as for fluctuation in picture goal. Quality and procurement. It performs very well in identifying pictures.

Disadvantage: This investigation requires total DR reviewing the injury, for example, exudates, cotton fleece spots to be thought of.

SurbhiSangwan et.al [5] illustrated the Identification of Different Steps of Diabetic Retinopathy This work presents distinctive eye maladies like Diabetic Retinopathy, Cataract and Glaucoma which causes our eye harm. In this work, a PC based methodology have been proposed in which the highlights are separated from these pictures utilizing picture preprocessing and outfit into the SVM utilizing Sequential insignificant improvement calculation. This paper gives a premise of characterization of Normal, NPDR or PDR influenced eye with high precision level of 92.6%.

Advantage: The outcomes reinforce the possibility that SVM can be utilized effectively and proficiently as a classifier for identifying eye related sicknesses caused by diabetes.

Disadvantage: This work would not give wanted outcomes in the event that the exudates territories at a specific segment in fundus surpass that of optical circle size.

Thomas Walter et.al [6] proposed A Contribution of Images Processing in the Diagnosis of Diabetic Retinopathy Detection which Exudates in Color Fundus Images of the Human Retina. In the system of PC helped analysis of diabetic retinopathy, another calculation for discovery of exudates is introduced and examined. The nearness of exudates inside the macular local is a primary sign of diabetic macular edema and permits its recognition with a high affectability. Primary sign of diabetic macular edema and permits its recognition with a high affectability. The calculation has been tried on a little picture information base and contrasted and the presentation of a human grader. Subsequently, we get a mean affectability of 92.8% and a mean prescient estimation of 92.4%. Strength regarding changes of the boundaries of the calculation has been assessed.

Advantage: The outcomes are empowering and a clinical assessment will be attempted so as to have the option to coordinate the introduced calculation in an apparatus for determination of diabetic retinopathy.

Disadvantage: Distinction in between hard fundus and soft exudates isn’t possible with the proposed algorithm.

V Saravanan. [7] Presented an Automated red lesion detection [7] in diabetic retinopathy. Retina is damaged in the human

eye to DR patients, it causes complications such as increment in the glucose level and sugar level which can lead to loss of sight. The highest chance of developing DR in the longer diabetes patients. Microaneurysms are one of the initial symptoms of DR. The severity of disease indicates the number of microaneurysms used. Utilizing MATLAB code the proposed technique is utilized for the recognition of microaneurysms by utilizing morphological procedure. This proposed technique is utilized to characterize various stages: gentle, moderate and serious. In light of the characterizations DR is identified and contrasted into four phases based on checked distinguished microaneurysms.

Advantage: It devours lesser time than the progression shrewd screening process by an ophthalmologist.

Disadvantage: This method does not give more accuracy compared to other.

S. Shekar. [8] Restriction of optic circle and fovea in retinal fundus pictures. In the proposed technique, the retinal fundus pictures are utilized in the conclusion and treatment of different eye malady that are DR and glaucoma. Diabetic retinopathy is damage to retina. It can be affected people with diabetes is diabetic retinopathy and it develops a problem in their eyes. Glaucoma is also a one type of eye disease where fluid pressure interior the eye. It causes optic nerve injury. A computer aided analysis in fundus pixels could provide a rapid detect and characterization of retinal features. Using morphological operations and by using the Hough transform optic disk and the fovea is localised.

Advantage: Picture examination and preparing has extraordinary importance in the field of medication.

Disadvantage: The work would not give desired results in this analysis.

III. METHODOLOGY

The proposed architecture steps are anxious with fundamental system for framework architecture. It contains actual part of the framework architecture. It contains actual part of the framework in architecture and exchange between the segments. The proposed architecture system are as shown in the below Figure 4.1. The initial step is image acquisition. Image acquisition will take as an initial step for work flow sequence and without taking an image no processing is happened. Retinal images are taken by a mydratic and non mydratic camera. This camera is used for taking retinal photographs. In the detection of Glaucoma and DR the blood vessel segmentation is very important part to detect disease. Optical coherence tomography (OCE) the fundus images used for diagnosis of glaucoma and DR. blood vessel segmentation is the most important part in glaucoma and DR are characterized. After ISNT ratio calculation the severity of disease is finalized and detected.

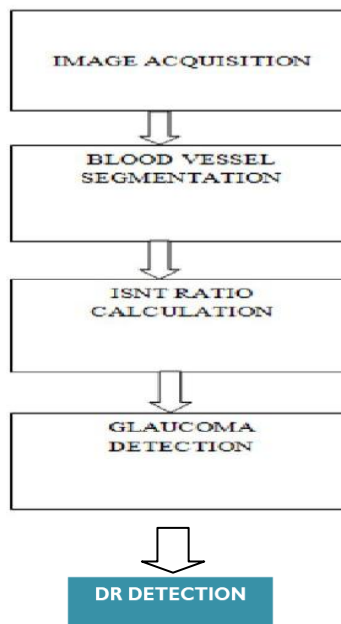


Figure 4.1: Proposed architecture

Implementation Details.

Input: image datasets with offline features. Description: pre-processed image datasets of 'N' images with 'K' sets are extract offline features.

Output: 'N' is labeled from 0 to total number of images.

Random Forest Algorithm

Random Forest Algorithm is also known as Supervised Learning Algorithm. The forest that construct the decision trees. The most important is bagging method, it is used to combine the learning models to increase the results.

Algorithm steps for Random Forest Algorithm.

The Successive **basic steps** are involved in performing the random forest algorithm:

Step 1: Input 'N' random images from the taken datasets.

Step 2: Based on these 'N' random images, it will construct a decision tree for every data set. Step 3: It will get a prediction result from every decision tree.

Step 4: select the no of trees in the algorithm and repeat step 1 and step 2.

Step 5: voting will perform for every prediction result.

Step 6: select the most voted prediction result as the final prediction result as output.

Step 7: If the regression problem is taking place for a new dataset, the tree forest predicts the value of output (y). The last value is calculated by minimum average values for all predicted trees in forest.

Support Vector Machine

Support Vector Machine are used for both categorized and reverting the process and hyper planes are split into two data sets classes. Support Vector Machine is also known as supervised machine learning algorithm.

Support Vector Machine Algorithm:

The Algorithm used linearly separable & nonlinear separable Datasets are used. It works well with limited datasets are used. Following steps are elaborate in executing the Support Vector Machine Algorithm.

Step 1: input the images.

Step 2: look at the shape of the images for some time.

Step 3: Layer the images in to train and test to utilize SK learn to construct the algorithm

Step 4: input the SVM classifier function.

Step 5: predict the values using SVM algorithm model. Step 6: Simplify the SVM model.

Step 7: output.

Implementation setup

The datasets and datasets are the similar functions carryout the function and decide to the type of the image to upload. It is a quick and efficient process. The stages are classified in to some steps. All the square boxes define their own features. The phases are independent to each other. The implementation setup are as shown in Figure 5.2.1.

- Training.
- Feature extraction.
- Testing.
- Evaluating model.

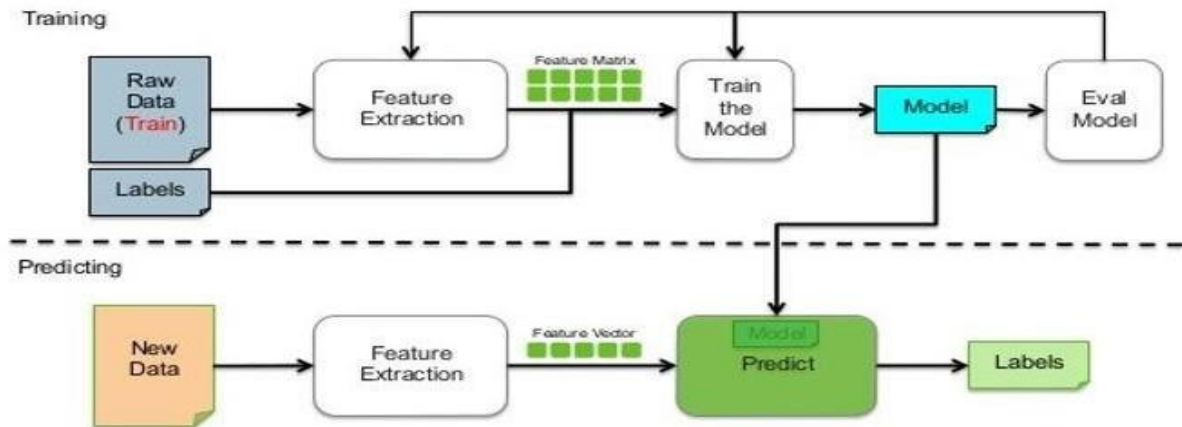


Figure 5.2.1: Implementation Setup.

The above Figure 5.2.1 shows the implementation setup of the system. It is very similar to the architecture described in the previous chapter. The square fields are divided into 9 columns. The admin plays very important key role for to collecting the input images and produces the output. The setup done is very easy and useful.

MODULES: The proposed system consists are five modules of following steps to interpret the gesture from the input image such as:

Data Collection (Fundus images):

The blood vessel segmentation are done through DRIVE (Digital Retinal Images) datasets. These images are digital and (RGB) Red: Green: Blue: Images are used to detect the disease. For to detect High Resolution pixels are used for the blood vessel dissection and train dataset images are observed by one person. And data set contains some of the images as 45 degree FOV and also include ground truth image.

Pre-processing and segmentation:

Preprocessing step is the first step for image improvement. Preprocessing is required for the initial step. In the preprocessing stage the RGB images are taken for to convert it into gray color. After converting the RGB color to gray the segmentation process starts. Two preprocessed images are necessary for blood vessel segmentation. The green channel extraction is the starting step after this image improvement is performed and it involves contrast improvement. Contrast improvement increases the visibility of the image. To make the blood vessels image clear every image value should be squared and normalized in the range of (0, 1) it is the improvement step to make vessels darker. The darker blood vessels are obtained by taking low pass filter and median filter of size (25*25): it correspond to high frequency of pixel. To obtain high pass filter and low pass filter pixel is subdivided in to enhanced image. The high pass filtered image is threshold to extract the images less than zero, so from this it will get initial preprocessed image to obtain second preprocessed image. Next step is the red regions are extracted from 12 linear structuring elements are rotated through 15 degree to get the tophat reconstruction pixel. It is used to extract the details of the image. Mean value of every image is final constructed image. Two preprocessed image are threshold to get the binaryimages.

Feature Extraction:

The Feature Extraction step is need to extract the definite feature. That are unique for every fundus pixel. The decision will take if the retinal is present in that image. The last features and frames are taken in to reflection. The Feature Extraction is extract the features in all Images (Retinal) dataset are store in SVM Model, RF Model and finally extract the labels best on train data and test data.

Classification:

Classification of retinal is done with the help of various features calculated previously. To recognition and utilization the recognized fundus images are generated uniquely. Five bit binary order is gives rise too uniquely. The recognized fundus images are supporting for human computer interaction. By the feature extraction significant peak is encrypt as one while insignificant peak is encrypt as zero place on joining to the threshold line.

Results analysis:

The different kind of fundus pixels are tested to find the new technique and new classification for to give a better accuracy results. Other pixels are tested and some data base pixels are shown in the result analysis. In Results analysis

are real time detect the Diabetic Retinopathy, Glaucoma and Healthy, when detect the Glaucoma then compare the features 'SVM. Model' and 'RF. Model' if the model is match the test data after the process in display the result.

IV. EXPERIMENTAL RESULTS

The results are analysed in all the formats and last point of results are depicted in the form of images. After calculating the collection of datasets. Some of the 10 images are taken for calculation. Those images are different and works manually by the user. Admin is taking responsible for to control submissions are followed in the system.

Results: Snapshots

Image masking

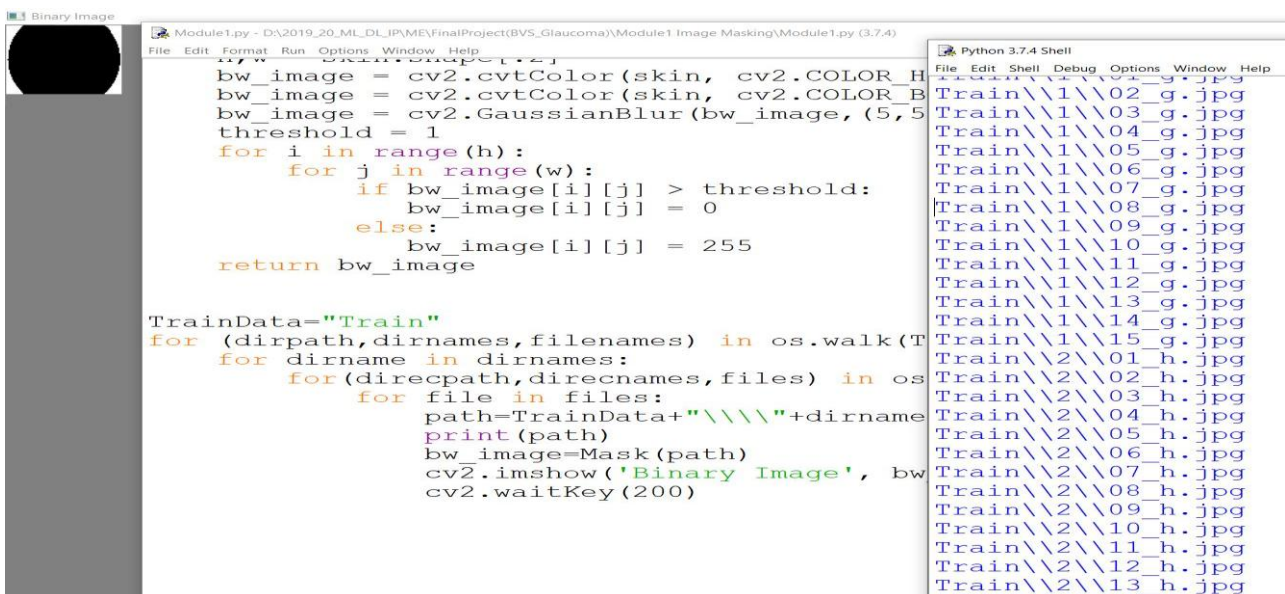


Figure 6.2.1: Image Masking.

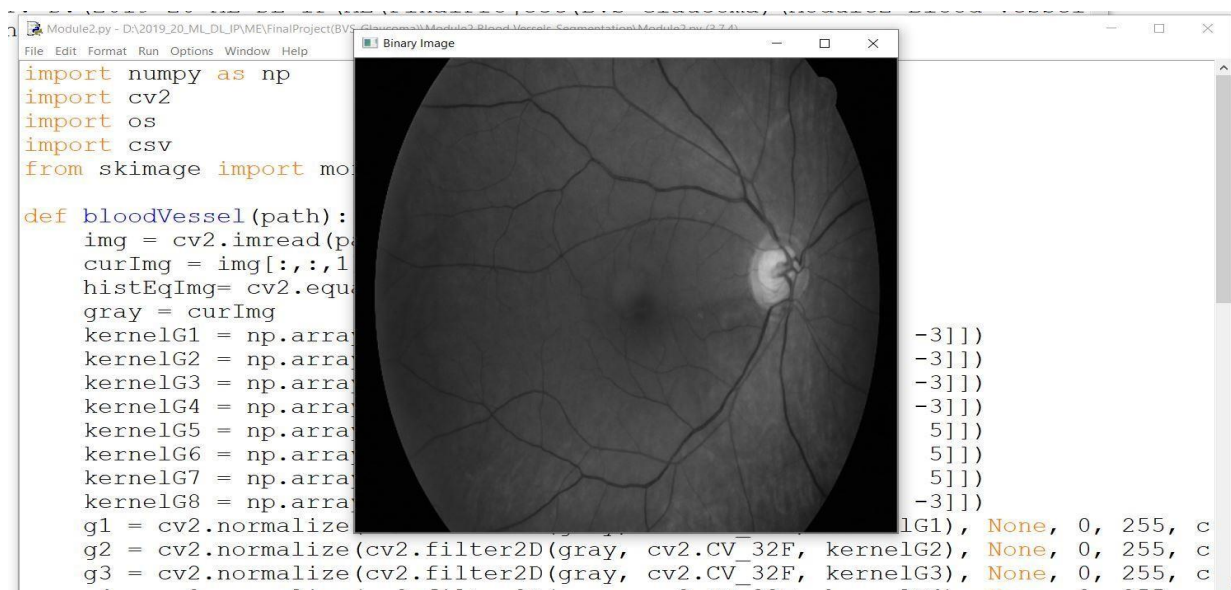

Figure 6.2.2: Blood Vessel Segmentation.

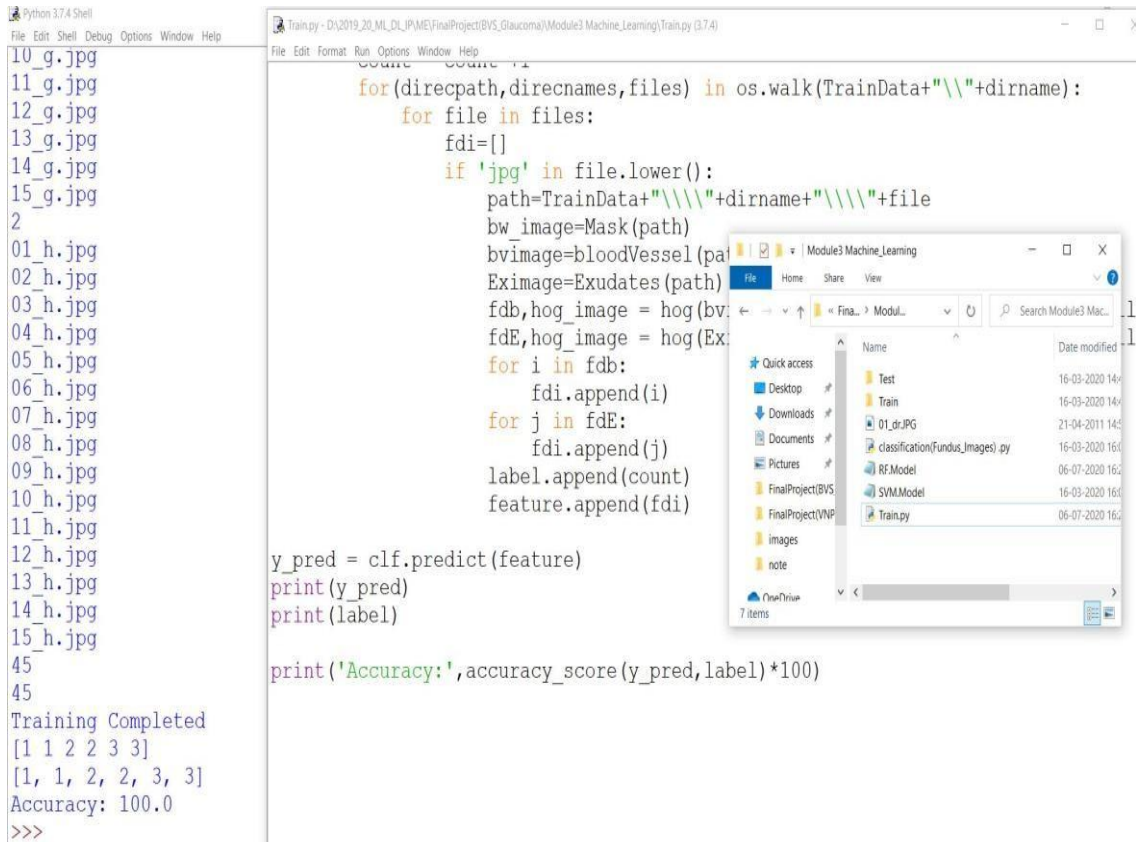


Figure 6.2.3: Folders Having Training Datasets.

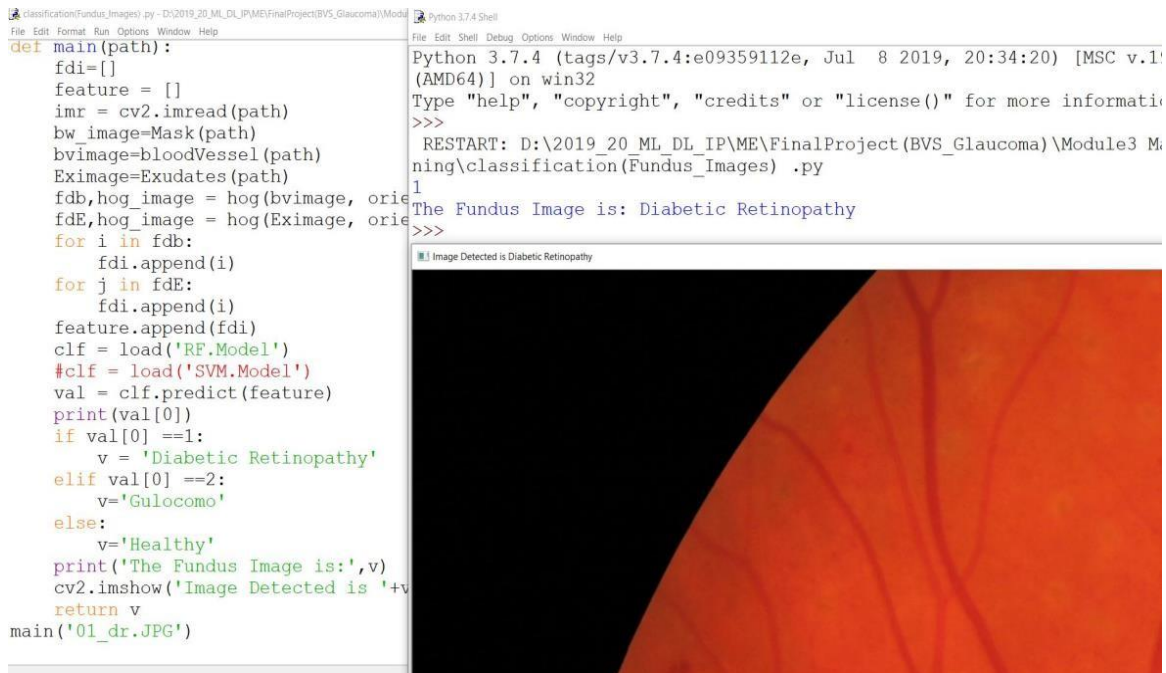


Figure 6.2.4: Classification.

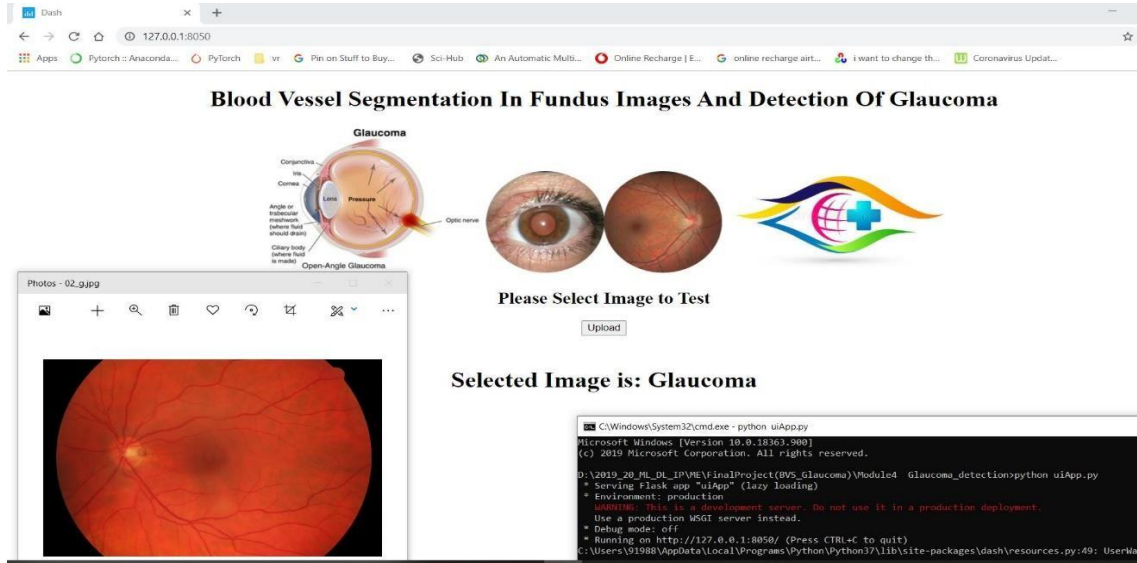


Figure 6.2.5: Final Detection of Glaucoma.

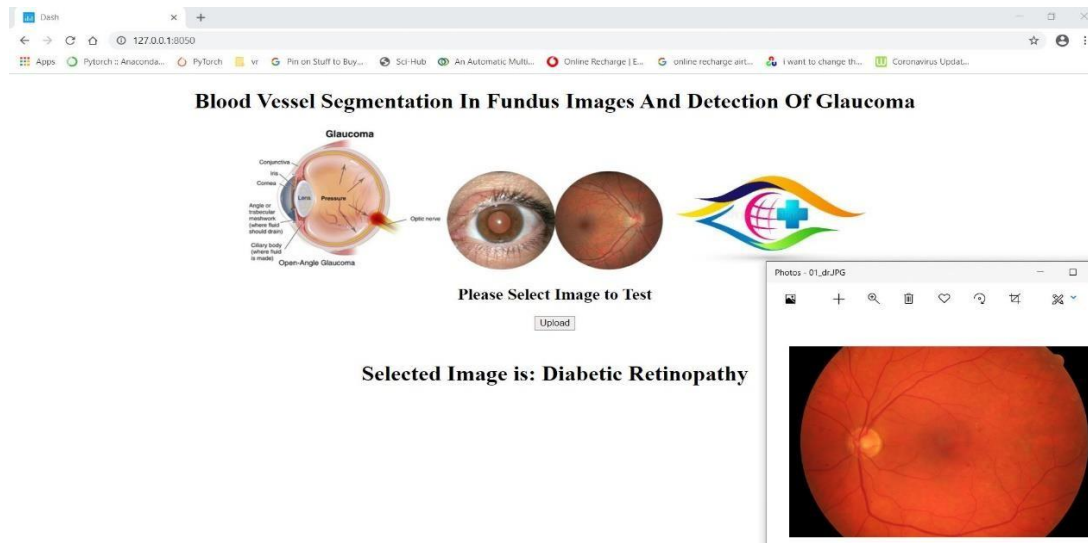


Figure 6.2.6: Final detection of Diabetic Retinopathy.

Table 6.1: ISNT Ratio Calculation are done Through Normal Persons on 10 images.

Image number	ISNT ratio
1	2.1423
2	2.4064
3	2.4149
4	1.9378
5	2.0355
6	2.0140
7	1.9418
8	2.2399
9	2.1186
10	2.4049



Table 6.2: ISNT Ratio Calculation are done Through on Glaucoma affected Person on 10Images.

Image number	ISNT ratio
1	1.8337
2	1.8108
3	1.7794
4	1.8111
5	1.6112
6	1.7146
7	1.8574
8	1.6520
9	1.7061
10	1.7788

V. CONCLUSION

The eye diseases cause blindness. A Huge people are affected through eye disease. So it is principal to find out the disease in primary stages to control the eye disease. For the detection of glaucoma, the initial stage is blood vessel segmentation has to be done. The two algorithms are used in this proposed method Support Vector Machine & Random Forest Algorithm. The proposed method gives good accuracy. Diabetic retinopathy also detected. The method is time saving and Glaucoma & Diabetic Retinopathy detected directly without detecting the lesions. This proposed method reduces the number of steps to detect lesions. The important goal of this technique is to decrease the classification error.

REFERENCES

[1] A. Mendonca, and A. Campilho, “Segmentation of retinal blood vessels by combining the detection of centerlines and morphological reconstruction,” IEEE Trans. Med. Imag., vol. 25, no. 9, pp. 1200–1213, Sep.2006.

[2] D. Marin, A. Aquino, M. Gegundez-Arias, and J. Bravo, “A new supervised method for blood vessel segmentation in retinal images by using gray-level and moment invariants-based features,” IEEE Trans. Med. Imag., vol. 30, no. 1, pp. 146–158, Jan.2011.

[3] S. Sekhar, “Automated localisation of optic disk and foveain retinal fundus images”, EUSIPCO2008.

[4] V. Saravanan. “Automated red lesion detection in diabetic retinopathy”. 978 -1-4673. IEEE Trans.2013.

[5] Lama seoud*, “Red lesion detection using dynamic shape features for diabetic retinopathyscreening”.IEEETrans.vol.35.No.4.April2016.

[6] MohdFazliHashm.“Diabetic retinopathy lesion detection using region based approach”. IEEE Trans.2014.

[7] A. Budai, R. Bock, A. Maier, J. Hornegger, and G. Michelson, “Robust vessel segmentation in fundus images,” Int. J. Biomed. Imag., article 154860, 2013, doi:10.1155/2013/154860.

[8]A. Hoover, V. Kouznetsova, and M. Goldbaum, “Locating blood vessels in retinal images by piecewise threshold probing of a matched filter response,” IEEE Trans. Med. Imag., vol. 19, no. 3, pp. 203–210, Mar.2000.

[9]J. Staal, M. Abramoff, M. Niemeijer, M. Viergever, and B. van Ginneken, “Ridge-based vessel segmentation in color images of the retina,” IEEE Trans. Med. Imag., vol. 23, no. 4, pp. 501–509, Apr.2004.

[10]M. M. Fraz et al., “Blood vessel segmentation methodologies in retinal images—A survey,” Comput. Methods Programs Biomed., vol. 108, no. 1, pp. 407–433,2012.

[11] J. V. Soares et al., “Retinal vessel segmentation using the 2-D Gabor wavelet and supervised classification,” IEEE Trans. Med. Imag., vol. 25, no. 9, pp. 1214–1222, Sep.2006.

[12] X. You et al., “Segmentation of retinal blood vessels using the radial projection and semi- supervised approach,” Pattern Recog., vol. 44, no. 10, pp. 2314–2324,2011.

[13] kosecemel, “Automatic segmentation of age-related macular degeneration in retinal fundus images”, department of computer engineering ,faculty of engineering ,karadeniz technical university2008.

[14] NamitaSengar, “Detection of Diabetic Macular Edemain Retinal Images Using a Region Based Method”, IEEE Transaction2015.

[15] S.T. Lim, “Automatic Classification of Diabetic Macular Edemain Digital Fundus Images”, IEEE Colloquium on Humanities, Science and Engineering Research (CHUSER 2011), Dec 5-62011.

[16] H. Jelinek , “Data fusion for multi-lesion diabetic retinopathy detection,” in Proc. IEEE Comput. Based Med. Syst., 2012, pp. 1–4,2011.

[17] www.iana.org

[18] <https://slogix.in>

[19] <https://anrg.usc.edu/contiki>