

International Journal of Innovative Research in Science, Engineering and Technology

(A High Impact Factor, Monthly, Peer Reviewed Journal)

Visit: www.ijirset.com

Vol. 9, Issue 1, January 2020

Clear Classification of Blood Vessels from the Diabetic Retinopathy Image using Well-Organized Algorithms

Sujeetha D, Dr.K. Venkatasalam,

Department of Computer Science Engineering, Mahendra Engineering College, Mallasamudram, Namakkal, India

Department of Computer Science Engineering, Mahendra Engineering College, Mallasamudram, Namakkal, India

ABSTRACT: Diabetic retinopathy (DR) is one of the major sight threatening diseases which can even causes blindness among working age people. In this paper we are going to analyze the computer based fundus image of the Diabetes mellitus (DM) patient in order to determine whether the person is affected by DR or not and also identify the severity level of the DR. The Morphological Algorithm has been implemented in order to perform image processing of the given fundus image. The support vector machine classifier is used for the classification of the severity level of the disease and identify the successive stages of the diseases. After detection of blood vessel, Microaneurysms and exudates, we can classify the groups as either affected or normal depending on the count of detected blood vessel, Microaneurysms and exudates. Classification can be used to grade the DR into three stages as normal DR, mild DR and severe DR.

I. INTRODUCTION

Diabetic Retinopathy is a major complication for diabetic patients which may cause blindness to the working population of people around the world. The disease can be recognized only by monitoring the patient's retinal changes. It progresses gradually so that the treatment becomes complicated and nearly impossible which lead to inevitable vision loss if it is unnoticed for a long time. Diabetic retinopathy occurs when there is damage in the blood vessels that nourish tissues and nerve cells in the retina. Regular screening of diabetes can lessen the risk of blindness in the patients by around 50%. Diabetic retinopathy is caused mainly due to diabetes such as diabetes mellitus and diabetes insepidious. It is a very asymptomatic disease which will not be able to detect during the early stages and it could lead to permanent vision loss if untreated for long time.

The stages of diabetic retinopathy are classified into Non proliferative diabetic retinopathy (NPDR) and proliferative retinopathy (PDR). NPDR is the starting stage of Diabetic retinopathy. It is a micro vascular complication of diabetes mellitus that may even lead to vision loss. In this case, at least one microaneurysm with or without the presence of retinal haemorrhages or hard exudates or cotton wool spots or venous loops may be present in the retina. Microaneurysms are the first clinical abnormalities which are to be noticed in the eye. They might appear like isolation or clusters as very small, dark red spots or looks like tiny hemorrhages within the light sensitive retina. Depending on the availability of the features including retinal hemorrhages, hard exudates, microaneurysms or cotton wools spots occurs due to leakage of fluid and blood in the blood vessels, NPDR is classified into i) mild, ii) moderate and iii) severe. In mild NPDR, microaneurysms will be like a small area of balloon-like swellings in the tiny retinal blood vessels. As the disease progresses, some blood vessels that nourish the retina will get blocked and this stage is called Moderate NPDR. The next stage is Severe NPDR during which enormous amount of blood vessels will get blocked.

The primary sign of diabetic retinopathy is exudates, if diabetic retinopathy is detected at an early stage, then the blindness of diabetic patients can be prevented. There are various approaches for detection of exudates in diabetic retinopathy. In this paper we have developed a morphology-based system for detection of whether the patient has the

International Journal of Innovative Research in Science, Engineering and Technology

(A High Impact Factor, Monthly, Peer Reviewed Journal)

Visit: www.ijirset.com

Vol. 9, Issue 1, January 2020

diabetic retinopathy or not. The Naïve Bayes classifier has been used for the classification of the disease based on the severity level.

II. DIABETIC RETINOPATHY DETECTION SYSTEM

The detection of Diabetic Retinopathy is a fully automated system. Input to this system is a fundus image which is a detected part of human eye that can be seen through the pupil. The fundus image is not uniform and suffers from non-uniform illumination, lighting variations, poor contrast and noise so pre-processing is used to get better results. The proposed method consists of three fundamental parts, (1) pre-processing, in which an gray image is obtained from green channel, background normalization, image binarization and contrast enhancement (2) feature extraction of microaneurysms based on its circularity and area , detection of exudates and hemorrhages (3) Classification based on count, thereby we can grade the severity.

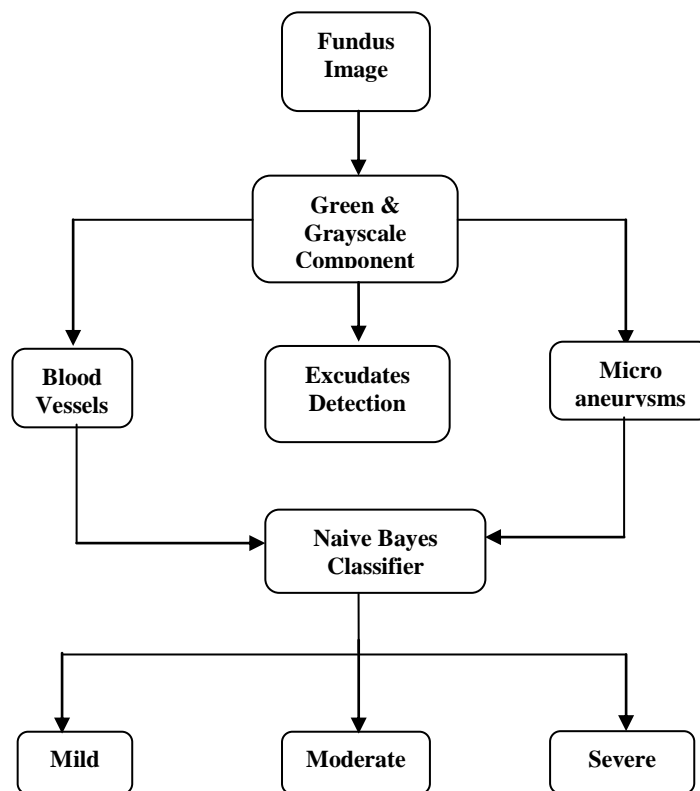


Fig 2 Overall Block Diagram for Detection of DR

Algorithm used: The algorithm used in this process is Morphological Algorithm. It is useful to extract image components that are useful in the representation of shape of the region such as boundaries extracted, skeletons, convex hull, morphological filtering, thinning and pruning.

International Journal of Innovative Research in Science, Engineering and Technology

(A High Impact Factor, Monthly, Peer Reviewed Journal)

Visit: www.ijirset.com

Vol. 9, Issue 1, January 2020

III. PREPROCESSING

The main aim of pre-processing is to attenuate the noise, improve the contrast and correct the non-uniform illumination. In RGB image processing, the green channel exhibit the best contrast between the vessels and background while the red and blue ones tend to be noisier. Hence green channel is used for further processing.

The next step is to convert a green channel image into a gray scale image, as the retinal blood vessels will appear dark in the gray image. All the features like blood vessels, MAs etc get hidden in the background and they will not be clearly visible. Thus the Normalization and contrast enhancement is used to improve the quality of image. The Normalization is performed by eliminating an approximate background from the gray image. An adaptive Histogram Equalization is applied for contrast enhancement. Darker regions including vessels, MAs, exudates and noise will become dominant after contrast enhancement. The gray threshold is selected to determine the blood vessels, Microaneurysms and exudates. The last step in the preprocessing is binarization. The candidate vessels, MAs and exudates are binarized by using multi-level thresholding technique. A correct threshold value is very crucial, because smaller threshold value may induces more noise and higher threshold value may causes loss of some fine vessels. After preprocessing the output image will be ready for feature extraction.

IV. FEATURE EXTRACTION

Objective of Feature Extraction is to extract the blood vessels, Microaneurysms and exudates present in the pre-processed image. The features such area, centroid, perimeter, orientation, filled area, Eccentricity, Equiv diameter, Pixel list are used to determine the threshold value of the microaneurysms, Hemorrhages and exudates.

Micro aneurysms are dark reddish in color, they appear as small red dots of 10 to 100 microns diameter and are circular in shape. Exudates are yellow-white patches of varying sizes and shapes. After the image has been pre-processed the candidate microaneurysms and exudates are segmented. MA and blood vessels both appear in a reddish color and exudates are the yellow patches. MAs and exudates cannot occur on blood vessels. Blood vessels are large in area and are connected component, that can be identified from MA and exudates based on area.

In order to remove blood vessels, objects having area greater than the threshold value are eliminated. The result image may include microaneurysms, exudates and some noise which are unconnected vessels and other particles in fundus image. MAs are circular 10-100 microns diameter in size and exudates are larger in size, thus MAs and exudates can be identified through noise based on area. Two threshold values are decided based on experimentation to remove noise objects having area greater and lesser than MAs and exudates.

The MAs will be circular in shape, it can be identified from noise and it is irregular in shape and then the remaining exudates are identified. Based on the major and minor axis, it is possible to eliminate the noise having same area as microaneurysms but are elongated in shape. At last, microaneurysms are detected based on its perimeter and circularity. The exudates are identified they are of irregular shapes and are the yellow patches. The exudates are the brighter region, while the microaneurysm are darker and smaller region.

V. CLASSIFICATION

After detection of blood vessel, Microaneurysms and exudates they can be classified either as diseased or normal depending on the count of detected blood vessel, Microaneurysms and exudates. The Support vector machine classifier has been used in this system for classify the DR based on severity grade. Classification can be used to grade the DR into three stages as normal DR, mild DR and severe DR.

Naive Bayes: Naive Bayes method is a set of supervised learning algorithms based on application of Bayes law with “naive”, assuming the independence between each and every pair of features. Given a class variable y and a dependent feature vectors x_1 through x_n Bayes’ theorem states the following relationship:

International Journal of Innovative Research in Science, Engineering and Technology

(A High Impact Factor, Monthly, Peer Reviewed Journal)

Visit: www.ijirset.com

Vol. 9, Issue 1, January 2020

$$P(y | x_1, \dots, x_n) = \frac{P(y)P(x_1, \dots, x_n | y)}{P(x_1, \dots, x_n)}$$

Using naive independence assumption, we can assume that

$$P(x_i | y, x_1, \dots, x_{i-1}, x_{i+1}, \dots, x_n) = P(x_i | y),$$

for all i , this relationship is simplified to

$$P(y | x_1, \dots, x_n) = \frac{P(y) \prod_{i=1}^n P(x_i | y)}{P(x_1, \dots, x_n)}$$

Since $P(x_1, \dots, x_n)$ is constant for the given input, we can use the following classification rule:

$$\begin{aligned} P(y | x_1, \dots, x_n) &\propto P(y) \prod_{i=1}^n P(x_i | y) \\ &\Downarrow \\ \hat{y} &= \arg \max_y P(y) \prod_{i=1}^n P(x_i | y), \end{aligned}$$

and we can use Maximum A Posteriori (MAP) estimation to estimate $P(y)$ and $P(x_i | y)$; the former is the relative frequency of class y in the training set.

The different Naive Baye's classifier differs mainly due to the assumptions they make regarding the distribution of $P(x_i | y)$.

Despite their apparently over-simplified assumptions, Naive Baye's classifier has worked well in many real-world situations, especially in document classification and spam filtering. They require a small amount of training data to estimate the necessary parameters.

Advantages:

- Easy to implement.
- Good results obtained in most of the cases.
- More quicker.

VI. RESULT ANALYSIS

To validate our analysis, we have to implement blood vessel segmentation in retinal image by using MATLAB and by performing a serious of simulation based experiments to test its effectiveness.

International Journal of Innovative Research in Science, Engineering and Technology

(A High Impact Factor, Monthly, Peer Reviewed Journal)

Visit: www.ijirset.com

Vol. 9, Issue 1, January 2020

The figure1 describes the input image obtained from MESSIDOR dataset. Smoothing of the input image is shown in figure2. In RGB image processing, the green channel exhibit the best contrast between the vessels and background. So, it is necessary to filter green channel from the smoothed image and convert a green channel image into a gray scale image and it is shown in figure3.

In figure4, Normalization and contrast enhancement is done to improve the quality of image.

In order to properly segment the enhanced blood vessel segments in the matched filter response images, an effective thresholding is to be done to filter gray enhanced image at different angles, it is shown in figure5.

The figure6 and figure7 describes the segmented red lesions containing spurious regions and the corresponding blood vascular pattern.

The figure8 describes the gray scale image of candidate lesions after the elimination of blood vessels.

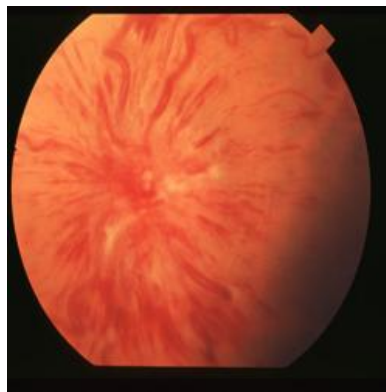


Figure 1 : Input image

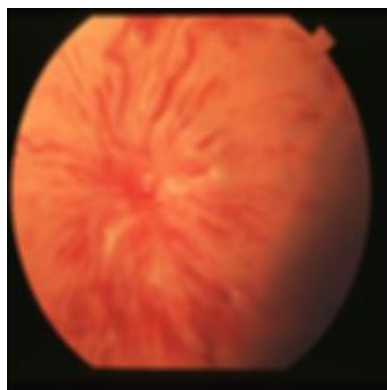


Figure 2 : Smooth image

International Journal of Innovative Research in Science, Engineering and Technology

(A High Impact Factor, Monthly, Peer Reviewed Journal)

Visit: www.ijirset.com

Vol. 9, Issue 1, January 2020

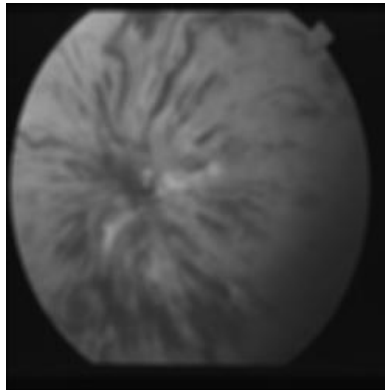


Figure 3 : Green channel image

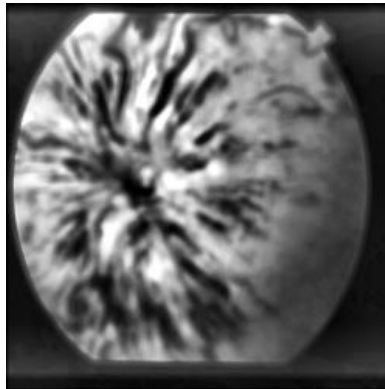


Figure 4 : Contrast Enhanced image

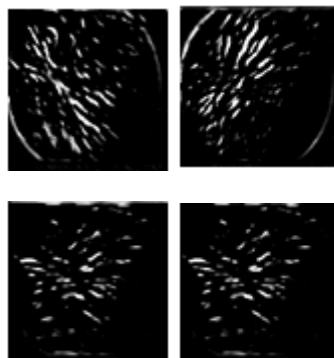


Figure 5 : Filtered image at different angles(45°, 90°, 135°, 180°)

International Journal of Innovative Research in Science, Engineering and Technology

(A High Impact Factor, Monthly, Peer Reviewed Journal)

Visit: www.ijirset.com

Vol. 9, Issue 1, January 2020




Figure 6 : Segmented red lesions




Figure 7 : Segmented blood vascular pattern




Figure 8 : Candidate lesions after vessel elimination

International Journal of Innovative Research in Science, Engineering and Technology

(A High Impact Factor, Monthly, Peer Reviewed Journal)

Visit: www.ijirset.com

Vol. 9, Issue 1, January 2020

VII. CONCLUSION

In this system we propose a screening detection of Diabetic retinopathy using fundus image in order to determine whether the person is affected by DR or not and its severity level. The proposed technique allows analyzing more images and characterizes many more properties of the retinal vasculature. The threshold value of the Microaneurysms, Hemorrhages and exudates are done using the various features such as area, centroid, pixel list, orientation, perimeter, filled area and eccentricity. The classification of the severity level into various grade are done by using Naive Bayes classifier by the obtained threshold value. The demonstrated effectiveness, together with its simplicity makes this adaptable system for early diabetic retinopathy detection and prevent the blindness.

REFERENCES

1. M. D. Abramoff, M. Niemeijer, and S. R. Russell, "Automated detection of diabetic retinopathy: Barriers to translation into clinical practice" in *Expert Rev. Med. Devices*, vol. 7, no. 2, pp. 287–296, 2010.
2. J. Cuadros and G. Bresnick, "Eyepacs- an adaptable telemedicine system for diabetic retinopathy screening," *J. Diabetes Sci. Technol.*, vol. 3, no. 3, p. 509516, May 2009.
3. B. Zhang, X. Wu, J. You, Q. Li, and F. Karray, "Detection of microaneurysms using multi-scale correlation coefficients," *Pattern Recognit.*, vol. 43, no. 6, pp. 2237–2248, 2010.
4. C. Agurto, V. Murray, E. Barriga, S. Murillo, M. Pattichis, H. Davis, S. Russell, M. Abramoff, and P. Soliz, "Multiscale AM-FM methods for diabetic retinopathy lesion detection" *IEEE Trans. Med. Imag.*, vol. 29, no. 2, pp. 502–512, Feb. 2010.
5. M. D. Abramoff, M. Niemeijer, M. S. Suttorp-Schulten, M. A. Viergever, S. R. Russell, and B. van Ginneken, "Evaluation of a system for automatic detection of diabetic retinopathy from color fundus photographs in a large population of patients with diabetes," *Diabetes Care*, vol. 31, no. 2, pp. 193–198, Feb. 2008.
6. S. Roychowdhury, D. D. Koozekanani, and K. K. Parhi, "Screening fundus images for diabetic retinopathy," in *Proc. Conf. Record 46th Asilomar Conf. Signals, Syst. Comput.*, 2012, pp. 1641–1645.
7. L. Xu and S. Luo, "Support vector machine based method for identifying hard exudates in retinal images," *Proc. IEEE Youth Conf. Inf., Comput. Telecommun.*, pp. 138–141, Sep. 2009.
8. C. I. Sanchez, M. Niemeijer, A. V. Dumitrescu, M. S. A. Suttorp-Schulten, M. D. Abramoff, and B. van Ginneken, "Evaluation of a computer-aided diagnosis system for diabetic retinopathy screening on public data," *Investigat. Ophthalmol. Vis. Sci.*, vol. 52, no. 7, pp. 4866–4871, 2011.
9. D. Welfer, J. Scharcanski, and D. R. Marinho, "A coarse-to-fine strategy for automatically detecting exudates in color eye fundus images," *Comput. Med. Imag. Graph.*, vol. 34, no. 3, pp. 228–235, 2010.
10. M. Esnaashari, S. A. Monadjemi, and G. Naderian, "A content-based retinal image retrieval method for diabetes-related eye diseases diagnosis," *Int. J. Res. Rev. Comput. Sci.*, vol. 2, no. 6, pp. 1222–1227, 2011.
11. B. Antal and A. Hajdu, "An ensemble-based system for microaneurysm detection and diabetic retinopathy grading," *IEEE Trans. Biomed. Eng.* vol. 59, no. 6, pp. 1720–1726, Jun. 2012.
12. E. Barriga, V. Murray, C. Agurto, M. Pattichis, W. Bauman, G. Zamora, and P. Soliz, "Automatic system for diabetic retinopathy screening based on am-fm, partial least squares, and support vector machines," in *Proc. IEEE Int. Symp. Biomed. Imag., Nano Macro*, Apr. 2010, pp. 1349–1352.
13. C. Agurto, E. Barriga, V. Murray, S. Nemeth, R. Crammer, W. Bauman, G. Zamora, M. Pattichis, and P. Soliz, "Automatic detection of diabetic retinopathy and age-related macular degeneration in digital fundus images," *Invest Ophthalmol. Vis. Sci.*, vol. 52, no. 8, pp. 5862–5871, Jul. 29, 2011.