

International Journal of Innovative Research in Science, Engineering and Technology

(A High Impact Factor, Monthly, Peer Reviewed Journal)

Visit: www.ijirset.com

Vol. 9, Issue 3, March 2020

Efficient Identification of Retinal Disease using Segmentation Algorithm

Shankara Kumaran S¹, Jason M², Anbarasan A³

U.G. Student, Department of Electronics and Communication Engineering, Valliammai Engineering College,
SRM Nagar, Tamilnadu, India¹

U.G. Student, Department of Electronics and Communication Engineering, Valliammai Engineering College,
SRM Nagar, Tamilnadu, India²

Assistant Professor, Department of Electronics and Communication Engineering, Valliammai Engineering College,
SRM Nagar, Tamilnadu, India³

ABSTRACT: The retinal image diagnosis is an important process in Diabetic Retinopathy(DR) cases. Exudates are the result of break down of the blood-retinal barrier and the leakage of serum proteins, lipids and protein from the vessels. It is the leading cause of blindness. To reduce the workload of ophthalmologists the retinal image of the affected eye was processed and the accuracy of the Exudates affected area was calculated. Through the Gray-Level Co-Occurrence Matrix(GLCM) feature extraction was done and the Random Forest Classifier technique algorithm was used to detect the stages of exudates. By using these algorithms the early detection of the exudates was possible and can be diagnosed at the starting stage of the exudates.

KEYWORDS: Retinal Image, Retinopathy, Exudates detection, Segmentation Algorithm.

I. INTRODUCTION

The retinal image diagnosis is an important methodology for diabetic retinopathy detection and analysis. It is used to detect diabetes in early stages by evaluating all the retinal blood vessels together. In this project, a novel algorithm called multi-resolution and normalized graph cut segmentation is proposed to detect the blood vessels, optic disc and Exudates detection in the retinal images efficiently. Exudates are presented as white or yellow bright structures in colour fundus image, with variable shapes and contrast [1]. To reduce the cost for Diabetic Retinopathy(DR) and considering the increasing number of diabetic patients this project was done. The various risk factors for diabetic retinopathy and its spectrum are still poorly understood in the Indian population, Mainly the exudates in the retina cannot be identified in its initial stage. Firstly, the colour fundus image of the patient was taken as the input image and it was a colour fundus image. The green channel was extracted from the input image and it gives the best result in the contrast of blood vessels. Image segmentation was done through Normal Gradient Technique(blood vessel) with curvelet transform and Modified Expectation-Maximization algorithm for exudates detection. The Feature Extraction was a machine learning technique [2] it was done through the Gray-Level Co-Occurrence Matrix (GLCM). Then the random forest classifier algorithm was used to classify the stages fo exudates [2]. Finally, the accuracy testing was done by the confusion matrix technique.

International Journal of Innovative Research in Science, Engineering and Technology

(A High Impact Factor, Monthly, Peer Reviewed Journal)

Visit: www.ijirset.com

Vol. 9, Issue 3, March 2020

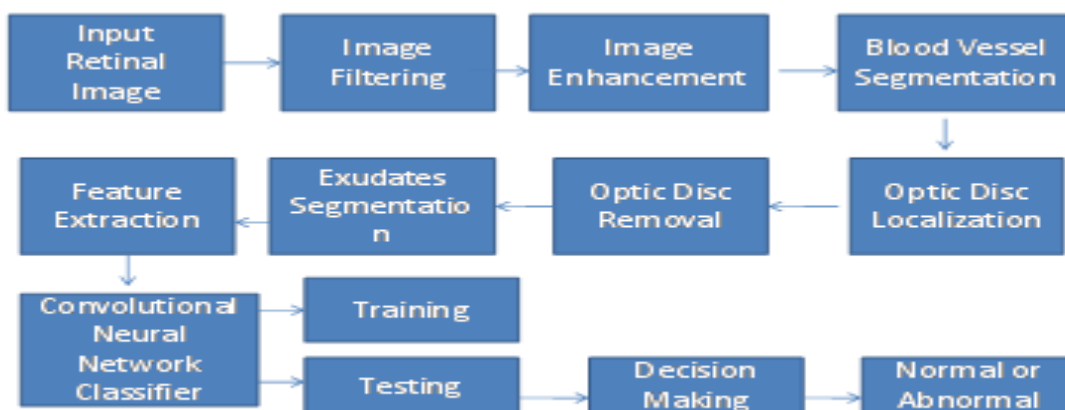
II. RELATED WORK

The survey from few papers gives us an overview on the existing system

- "Exudates Detection for Diabetic Retinopathy with CNN" proposed by Shuang Yu, Di Xiao and Yogesan Kanagasigam adopted CNN to achieve pixel-wise exudate identification.
- "Exudate Detection in Color Retinal Images for Mass Screening of Diabetic Retinopathy" Medical Image Analysis was done by X. Zhang, G. Thibault, Z. Victor and A. Erignay.
- "ImageNet Classification with Deep Convolutional Neural Networks" Advances In Neural Information Processing Systems by A. Krizhevsky, I. Sutskever, and G. E. Hinton.
- "Very Deep Convolutional Networks for Large-Scale Image Recognition" International Conference on Learning Representation by K. Simonyan and A. Zisserman.

III. METHODOLOGY

The colour fundus image was the input image in which the optic disc was a bright circular or elliptical region on the retinal image[1]. Image denoising was done through the median filter and 2D bilateral filter, These are the filters which are used for reducing the speckle noise and salt&pepper noise. Image enhancement was done by Contrast Adjustment algorithm and the Image segmentation was done by Modified Expectation-Maximization algorithm for exudates detection. Image feature extraction was done through Gray-Level Co-Occurrence Matrix (GLCM)[3] [4]. This was the most important step in which the stages of the exudates were classified through the Random Forest Classifier algorithm by using this algorithm we can identify how much the patient's eye was affected, Then the accuracy was being tested.



A. Image Filtering:

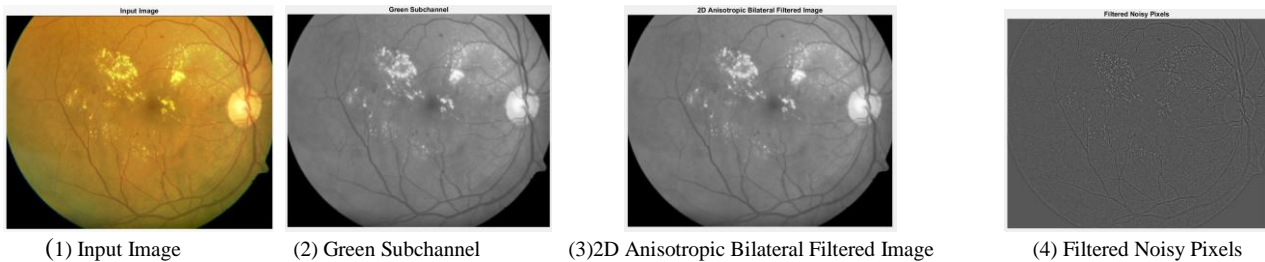Image filtering was done through the two filters they are median filter and 2D bilateral filter. The median filter was the filter which is used for the removal of salt & pepper noise and the 2D bilateral filter was used for smoothing the image. From the colour fundus retinal image the green channel was extracted and in the green channel image the salt&pepper noise and the speckle were removed and the picture was being smoothed. The colour fundus image was the input image shown on Fig(1), The green channel extracted from the input image shown on Fig(2), 2D bilateral filtered image shown on Fig(3), Salt&pepper noise and speckle noise which was removed shown on Fig(4).

International Journal of Innovative Research in Science, Engineering and Technology

(A High Impact Factor, Monthly, Peer Reviewed Journal)

Visit: www.ijirset.com

Vol. 9, Issue 3, March 2020

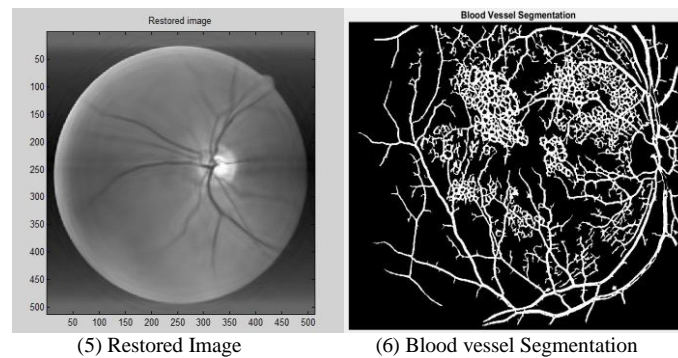


B. Image Enhancement:

The mean of each layer of the retinal image is recognized to improve its contrast and brightness of the image through the Adaptive Mean Adjustment algorithm.

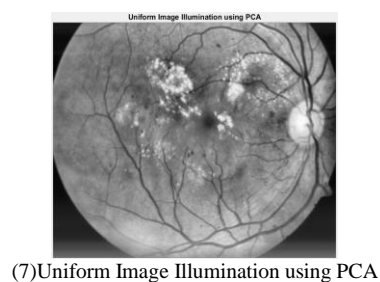
C. Image Segmentation:

The image segmentation was done through the Normalized Graph Cut Technique with Curvelet transform. Usually, a group of pixel or a pixel are joined with nodes and edges which define the dissimilarity between the neighbourhood pixels. The graph image was partitioned according to a criterion which was designed to model good clusters, Those partitioned pixels were considered as the segmented image. Fig(5) shows the restored image by Normalized Graph Cut Technique, Fig(6) shows the blood vessels are segmented by using normalized graph cut method.



D. Image Feature Extraction:

Image Feature Extraction was done with PCA(Principal Component Analysis) is a statistical procedure that uses an orthogonal transformation for converting a set of observation of possibly correlated variables into linear uncorrelated variables. Feature Extraction is the process of converting the raw data into a standardized embedded data [3][4]. Fig(7) shows the Uniform Illuminated Image using PCA.



International Journal of Innovative Research in Science, Engineering and Technology


(A High Impact Factor, Monthly, Peer Reviewed Journal)

Visit: www.ijirset.com

Vol. 9, Issue 3, March 2020

E. Image Classification:

In the Image Classification, there are two algorithms which are used they are Random Forest Classifier it is very effective in image recognition and classification [5]. Convolutional Neural Networks used for deep examining of the neural networks. The CNN consists of three layers: convolutional layer, pooling layer and fully connected layer [1]. Through EM algorithm the optic disc is segmented by morphological process of dilation and erosion shown on Fig(8).



(8) Optic Disc Segmentation

H. Final Segmentation:

GLCM is an effective tool for data extraction and the exudates affected area was being segmented. In this proposed system texture data features specifically contrast, Correlation, Energy, Homogeneity is estimated. The Random Forest Classifier is applied to classify whether its a normal eye or an abnormal eye. The Region Of Interest (ROI) is to comprise the exudates and that is carved out the complete image based on either clinical data or automatic segmentation. Fig(9) is the final image which shows the eye was affected or not.



(9) Final Segmentation – Exudates or non Exudates

IV. EXPERIMENTAL RESULTS

Table 1: Performance Analysis

Database	PSNR (Existing Median Filter)	MSE (Existing Median Filter)	PSNR (Proposed 2D anisotropic bilateral filter)	MSE (Proposed 2D anisotropic bilateral filter)
Image 1 – Normal	38.837	10.3879	48.8937	.0899
Image 2 – Abnormal	37.3878	9.8378	49.9378	.0937

International Journal of Innovative Research in Science, Engineering and Technology

(A High Impact Factor, Monthly, Peer Reviewed Journal)

Visit: www.ijirset.com

Vol. 9, Issue 3, March 2020

Table 2: Accuracy Testing using Confusion Matrix

Proposed Algorithm	Accuracy in %	Sensitivity in %	Sppecificity in %
CNN Classification	96	96	94

V. CONCLUSION

The retinal image analysis is processed using different algorithms to improvise its performance. The preprocessing algorithms are used to eliminate all the noise content in the image and enhancement technique is used to improve its brightness and contrast. The blood vessel segmentation is applied to estimate its thickness of the vessel to conclude the characteristics of the retinal image. The optic disc is entirely removed to avoid disease segmentation incorrectly. Once the optic disc is removed and then curvelet base normalized graph cut segmentation is applied to segment the disease like exudates. The performance analysis is tabulated to prove that high accuracy classification of disease detection of the real-time database.

REFERENCES

- [1] Shuang Yu, Di Xiao and YogesanKanagasigam, "Exudates detection for diabetic retinopathy with convolutional neural networks", 39th Annual International Conference of the IEEE Engineering in Medicine and Biology Society (EMBC), pp. 1718-9818, 2017.
- [2] T. A. Ciulla, A. G. Amador, and B. Zinman, "Diabetic retinopathy and diabetic macular oedema: Pathophysiology, screening, and noveltherapies," Diabetes Care, vol. 26, no. 9, pp. 2653–2664, 2003.
- [3] M. Niemeijer, B. Van Ginneken, S. R. Russell, M. S. A. Suttorp-Schulten, and M. D. Abramoff, "Automated detection and differentiation of drusen, exudates, and cotton-wool spots in digital colour fundus photographs for diabetic retinopathy diagnosis," Investigative Ophthalmology and Visual Science, vol. 48, no. 5, pp. 2260–2267, 2007.
- [4] T. Teng, M. Lefley, and D. Claremont, "Progress towards automated diabetic ocular screening: a review of image analysis and intelligent systems for diabetic retinopathy.," Medical & biological engineering& computing, vol. 40, no. 1, pp. 2–13, 2002.