



e-ISSN: 2319-8753 | p-ISSN: 2347-6710

IJRSET

International Journal of Innovative Research in
SCIENCE | ENGINEERING | TECHNOLOGY



INTERNATIONAL JOURNAL OF INNOVATIVE RESEARCH

IN SCIENCE | ENGINEERING | TECHNOLOGY

Volume 13, Issue 8, August 2024

ISSN INTERNATIONAL
STANDARD
SERIAL
NUMBER
INDIA

Impact Factor: 8.524

9940 572 462

6381 907 438

ijirset@gmail.com

www.ijirset.com

Segmentation, Classification, and Visualization of Intracranial Hemorrhage in CT Brain Images

G. Priyadharshini, R. Poomurugan

ME - VLSI Design, Gnanamani College of Technology, Namakkal, Tamilnadu, India

Assistant Professor, Gnanamani College of Technology, Namakkal, Tamilnadu, India

ABSTRACT: Intracranial hemorrhage (ICH) presents a significant threat to patient health, often necessitating prompt diagnosis and intervention. Over recent years, medical imaging technologies, particularly computed tomography (CT) scanning, have become indispensable for detecting and characterizing ICH. This article offers a comprehensive overview of state-of-the-art techniques for segmenting, categorizing, and visualizing intracranial hemorrhage in CT brain images. The review encompasses various methodologies, including traditional image processing techniques, modern machine learning algorithms, and deep learning approaches, highlighting their respective strengths, limitations, and potential applications in clinical practice. It also addresses the challenges associated with accurate ICH detection and quantification, such as the presence of artifacts, anatomical variations, and class imbalance.

Furthermore, the paper delves into emerging trends in ICH research, such as the integration of multimodal imaging data and the development of interactive visualization tools to enhance clinical decision-making. The segmented regions from each CT image are compiled into a unified 3D volumetric structure, providing essential information such as area, volume, and location. Additionally, the classification accuracy distinguishing between normal brain and ICH brain is reported at 95.8%. This 3D visualization, classification, and volumetric analysis of ICH can furnish neurologists with precise and crucial information necessary for effective ICH treatment.

KEYWORDS: Intracranial hemorrhage, CT brain images, segmentation, classification, visualization, image processing, machine learning, deep learning, medical imaging, clinical decision-making.

I. INTRODUCTION

Intracranial hemorrhage (ICH) is a critical medical condition characterized by bleeding within the skull. It encompasses various types, including epidural, subdural, subarachnoid, and intracerebral hemorrhages, each presenting unique challenges in diagnosis and management. ICH can result from various causes, such as trauma, vascular abnormalities, hypertension, coagulopathies, or underlying structural lesions. Regardless of the underlying cause, prompt identification and precise localization of ICH are crucial for initiating timely interventions and improving patient outcomes.

Medical imaging plays a pivotal role in the detection and characterization of intracranial hemorrhage. Among the modalities available, Computed Tomography (CT) imaging stands out as a cornerstone in the diagnostic workflow for brain-related pathologies. CT offers several advantages over other imaging modalities, including rapid acquisition times, high spatial resolution, and the ability to visualize both bony structures and soft tissues with excellent contrast resolution. This makes CT particularly well-suited for assessing acute hemorrhagic events in the brain, enabling clinicians to swiftly evaluate the extent and severity of bleeding.

The importance of early detection and accurate diagnosis of ICH cannot be overstated. Delayed or missed diagnosis may lead to devastating outcomes, including neurological deficits, permanent disability, or even death. Consequently, developing reliable and efficient methods for the segmentation, classification, and visualization of intracranial hemorrhage in CT brain images is of utmost importance.

Early detection of ICH is crucial for initiating timely interventions, such as surgical evacuation of hematomas or administration of anticoagulant reversal agents, which can significantly improve patient outcomes and reduce mortality

rates.

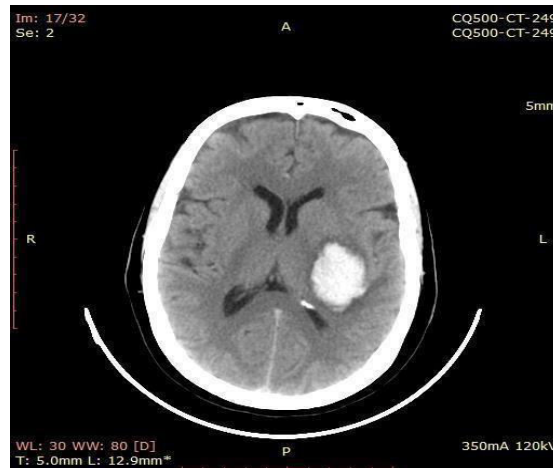

Fig 1.1 Intracranial haemorrhage CT brain image

Intracranial haemorrhage is defined as bleeding within the skull, as demonstrated in Figure 1.1

Moreover, accurate localization and characterization of hemorrhagic lesions are essential for guiding treatment decisions and assessing prognosis. For example, distinguishing between different types of ICH (e.g., traumatic vs. spontaneous, or intraparenchymal vs. subdural) is crucial, as their management strategies may vary significantly.

Intracranial hemorrhage is a significant contributor to mortality and disability and is categorized as a subtype of stroke. It can manifest spontaneously or in the context of trauma. Spontaneous intracranial hemorrhage may be linked to various pathological conditions, including but not limited to arteriovenous malformations, ruptured aneurysms, anticoagulation therapy, tumors, venous sinus thrombosis, hypertension, cerebral amyloid angiopathy, and hemorrhagic transformation of ischemic stroke. Traumatic intracranial hemorrhage can occur following any form of head trauma, with individuals on anticoagulant therapy facing a notably heightened risk. Intracranial hemorrhage constitutes a medical emergency, where swift diagnosis is paramount for enhancing patient outcomes, as patients frequently experience rapid deterioration within the initial hours of symptom onset.

II. BACKGROUND AND RELATED WORK

Intracranial hemorrhage (ICH) presents a complex and potentially life-threatening condition necessitating prompt and accurate diagnosis for appropriate clinical management. Researchers and clinicians have, over the years, investigated numerous approaches to automate the detection, segmentation, and classification of ICH lesions using medical imaging techniques, particularly computed tomography (CT) imaging.

Recent advancements have shifted towards machine learning (ML) and deep learning (DL) methods. ML algorithms like support vector machines (SVM), random forests, and gradient boosting machines (GBM) analyze features from hand-crafted descriptors and radiomic features extracted from CT images. However, these methods often rely on predefined feature sets and may struggle to capture complex spatial relationships within ICH lesions.

DL techniques, especially convolutional neural networks (CNNs), have emerged as powerful tools for automated medical image analysis. CNN architectures such as U-Net, Fully Convolutional Networks (FCNs), and DeepLab have demonstrated superior capabilities in learning hierarchical features from raw image data, enabling accurate and robust segmentation of hemorrhagic lesions. These DL-based approaches outperform traditional methods, particularly in challenging scenarios with heterogeneous lesion characteristics and variable imaging protocols.

EXISTING METHODS AND THEIR BARRIERS:

Despite the good sized development in automated ICH detection and analysis, several limitations persist. One commonplace challenge is the lack of massive-scale annotated datasets for schooling and validating system mastering fashions. Even as efforts were made to create publicly to be had datasets, which includes the RSNA Intracranial Hemorrhage Detection assignment dataset, those datasets may not completely capture the range of clinical eventualities encountered in real-world practice.

Every other hassle is the generalizability of present algorithms throughout exclusive imaging modalities, acquisition protocols, and patient populations. Many algorithms are skilled and evaluated on datasets from precise establishments or imaging protocols, which may additionally limit their applicability to other settings. Moreover, the interpretability of deep studying fashions stays a task, as those fashions often function as "black containers," making it difficult to apprehend the underlying choice-making method.

III. LITERATURE REVIEW**Danfeng Guo et al. (2020)**

Danfeng Guo and colleagues collected 1176 head CT scans, including 581 ICH patients and 595 normal subjects, to develop and evaluate their models. They utilized a combination of 3D and 2D ResNet18 architectures for classification and a 3D U-Net for segmentation. Their approach demonstrated the effectiveness of multi-task learning, where a single model simultaneously handles classification and segmentation tasks. They introduced the ICHNet model, which outperformed baseline models like ResNet18 and U-Net. Their findings indicated that models incorporating sequential information, such as those using ConvLSTM modules, achieved better performance in capturing the temporal dynamics of hemorrhage progression. The study emphasized the importance of attention mechanisms in improving segmentation accuracy, although their impact was less pronounced than multi-task learning.

Kai Hu et al. (2020)

Kai Hu and colleagues proposed a novel segmentation method using deep neural networks for ICH detection. Their approach, named ED-Net, consists of an encoder that extracts multi-scale features and a decoder that integrates these features to form a unified representation of ICH regions. They introduced a synthetic loss function designed to address the challenges of segmenting small hemorrhagic regions and handling data imbalance. Using a dataset of 480 cases from multiple hospitals, they compared their method against nine state-of-the-art segmentation approaches, including SegNet, U-Net, and DeepLabv3. The experimental results demonstrated that ED-Net outperformed the other methods, achieving superior segmentation accuracy, especially for small hemorrhagic regions.

Pankaj Singh et al. (2018)

Pankaj Singh and colleagues developed a hybrid method combining FCM (Fuzzy C-Means) clustering and MDRLSE (Modified Distance Regularized Level Set Evolution) for ICH segmentation in CT images. FCM clustering was used for initializing the level set function in MDRLSE, improving the accuracy of hemorrhage diagnosis. Their experimental results showed that the proposed method achieved higher segmentation accuracy compared to traditional methods.

Sumijan et al. (2017)

Sumijan and colleagues presented a method for segmenting and reconstructing hemorrhagic regions in 3D using a combination of Otsu's method and morphological operations. Their approach accurately segmented the hemorrhagic regions, calculated their area and volume, and performed 3D reconstruction. They applied their method to CT images, achieving precise separation of hemorrhagic regions from surrounding tissues. The study demonstrated that combining Otsu's method with morphological operations effectively segmented hemorrhagic regions, facilitating accurate volume calculation and 3D visualization.

IV. DATA ACQUISITION AND PREPROCESSING**Description of the Dataset:**

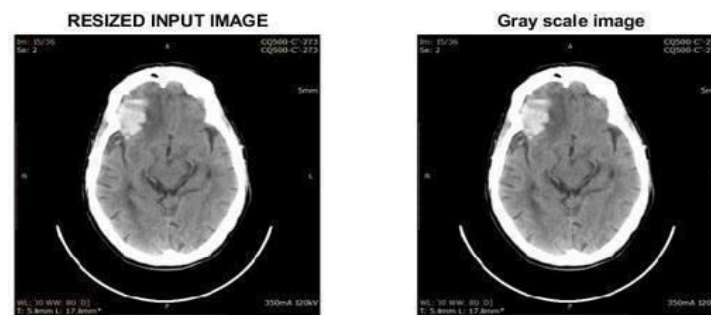
The study leveraged a comprehensive dataset of CT brain images from multiple medical institutions and research repositories. The dataset included diverse cases of ICH, covering acute and chronic conditions with varying severity, locations, and etiologies. Each CT scan was accompanied by detailed clinical metadata, including patient

demographics, relevant medical history, and imaging findings. The dataset was divided into training, validation, and testing subsets to ensure a balanced representation of positive and negative cases.

Preprocessing Steps:

2D sliced CT Intracranial haemorrhage image in RGB format. Image resizing is necessary to process a image and fix unique size of (256x256). Further the resized RGB image can be converted in to Gray scale image for performing image processing. Grayscale image in 8-bit representation will be a matrix, and the values can be anything from 0 to 255. 0 indicates black pixels and 255 indicate white pixels and in between different shades from black to white will come.

Image shown in Fig 4(a) can be resize in to(256x256). Resized image in RGB can be converted in togray scale image shown in fig 4(b).



(a) Resized image

(b) Grayscale image

Fig 4 & 4.2 Pre processed CT Intracranial haemorrhage

Prior to undertaking picture evaluation obligations, a series of preprocessing steps have been employed to standardize and decorate the excellent of the CT brain photographs:

1. **Noise Reduction:** Advanced denoising algorithms such as iterative reconstruction techniques and adaptive filtering were applied to suppress noise while preserving essential image features.
2. **Skull Stripping:** Robust skull stripping algorithms using morphological operations and intensity thresholding segmented the intracranial region from surrounding non-brain tissues.
3. **Intensity Normalization:** Techniques such as histogram equalization and rescaling intensity values standardized intensity characteristics across the dataset.
4. **Spatial Resampling:** Spatial resampling techniques ensured uniform voxel spacing and alignment across the dataset, optimizing images for analysis.

By using carefully imposing these preprocessing steps, we aimed to optimize the CT pix for next analysis, ensuring strong and reproducible effects in computerized ICH detection, segmentation, and characterization responsibilities. Furthermore, those preprocessing measures have been vital for minimizing artifacts, enhancing image quality, and facilitating the development of clinically relevant picture analysis algorithms.

V. SEGMENTATION OF INTRACRANIALHEMORRHAGE

Different Segmentation Techniques Employed:

Traditional Methods: Traditional segmentation approaches for ICH often rely on classical image processing techniques. These methods typically involve thresholding, where pixels or voxels with intensity values above a certain threshold are classified as hemorrhagic, and those below are classified as non-hemorrhagic. Region growing algorithms iteratively expand regions based on predefined criteria, such as intensity similarity or spatial connectivity.

Additionally, morphological operations, such as erosion and dilation, are employed to refine the segmented regions and remove artifacts.

Need to remove the Skull region for efficient segmentation by using connected components. Skull region identify by using thresholding method.

- The Pre processed image can be cluster by using K- means cluster. The clustered image shown in Fig 4.3.




Fig 4.3 K means clustered image

- Separate a each clustered region from k means algorithm contains presence of ICH region and absence of ICH region shown in Fig 4.4.

(a) ICH absent region (b) ICH present region Fig 4.4 Separated a Clustered region

- From the separated clustered region using the connected components and its length value to select the ICH present clustered region is shown in Fig 4.5.
- Length of ICH region is less than the length of absence of ICH cluster region.



Fig 4.5 ICH present clustered region

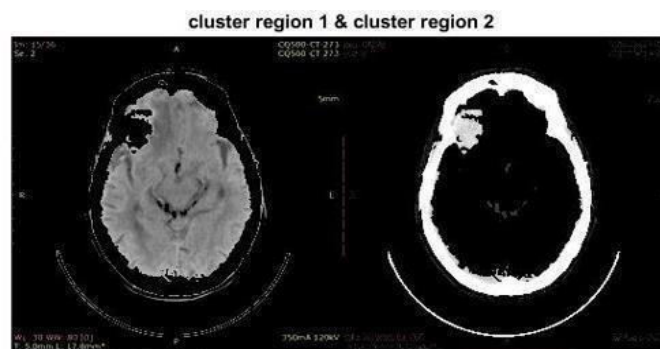
Machine Learning Approaches: ML-based segmentation techniques leverage statistical learning algorithms to automatically identify and delineate ICH regions within CT images. Supervised ML methods, such as SVM and random forests, learn discriminative features from annotated training data to classify pixels or voxels as belonging to hemorrhagic or non-hemorrhagic regions. Unsupervised ML techniques, such as k-means clustering, partition the image into clusters based on feature similarity, with hemorrhagic regions emerging as distinct clusters.

Deep Learning Techniques: DL-based segmentation methods have emerged as state-of-the-art approaches for segmenting ICH from CT images. CNNs are particularly well-suited for this task due to their ability to learn hierarchical features directly from raw image data. Architectures like U-Net, Fully Convolutional Networks (FCNs), and DeepLab employ encoder-decoder structures to capture contextual information and generate pixel-wise segmentation masks. DL-based approaches offer superior performance compared to traditional methods, as they can handle complex lesion morphologies and variations in imaging characteristics.

Evaluation Metrics Used for Assessing Segmentation Accuracy:

Dice Similarity Coefficient (DSC): The DSC measures the spatial overlap between the predicted and ground truth segmentation masks. It is calculated as twice the intersection of the predicted and ground truth masks divided by the sum of their sizes. A DSC value of 1 indicates perfect overlap, while lower values indicate poorer segmentation accuracy.

Jaccard Index (JI) or Intersection over Union (IoU): The Jaccard Index (also known as IoU) measures the overlap between the predicted and ground truth segmentation masks, normalized by their union. It is calculated as the intersection of the predicted and ground truth masks divided by the union of the two masks. Similar to DSC, higher values indicate better segmentation performance.



Sensitivity and Specificity

Sensitivity (true positive rate) measures the proportion of true hemorrhagic pixels or voxels correctly identified by the segmentation algorithm. In contrast, **specificity** (true negative rate) measures the proportion of true non-hemorrhagic pixels or voxels correctly identified. These metrics provide insights into the algorithm's ability to detect both positive and negative instances accurately.

Accuracy and Precision

Accuracy measures the overall correctness of the segmentation results, reflecting the proportion of true positive and true negative predictions among all instances.

Precision measures the proportion of true positive predictions among all positive predictions made by the algorithm. Together, these metrics offer a comprehensive assessment of segmentation performance, considering both true positive and true negative instances.

Hausdorff Distance

The **Hausdorff distance** quantifies the maximum distance between corresponding points in the predicted and ground truth segmentation masks. This metric provides a measure of spatial discrepancy between the two masks, with lower values indicating better alignment and agreement. The Hausdorff distance is particularly useful for evaluating the spatial accuracy of segmentation algorithms.

Evaluation and Insights

By utilizing these evaluation metrics, researchers can quantitatively assess the performance of segmentation algorithms and compare their accuracy and robustness across different methodologies and datasets. These metrics provide valuable insights into the strengths and limitations of segmentation algorithms, guiding further improvements and refinements in automated ICH detection and analysis.

VI. CLASSIFICATION OF INTRACRANIALHEMORRHAGE

Classification Algorithms: SVM, Random Forest, and CNNs were employed for classifying ICH. CNNs, in particular, demonstrated high effectiveness in processing structured grid-like data.

It works by finding the hyperplane that best separates different classes while maximizing the margin between them. SVMs can handle linear and non-linear classification problems using different kernel functions.

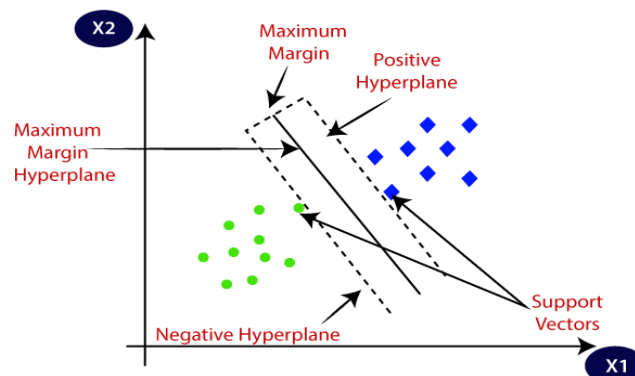


Fig 3 Linear SVM classifier

Feature Extraction and Selection: Handcrafted features and deep learning-based features were used for classification. Feature selection techniques, such as PCA and RFE, were employed to identify the most discriminative features.

Evaluation Metrics: Classification performance was evaluated using accuracy, precision, recall, specificity, F1 score, ROC curve, AUC, and confusion matrix.

VII. VISUALIZATION TECHNIQUES:


2D Visualization Techniques:

- Overlay Maps
- Heatmaps
- Contour Plots
- Slice-by-Slice Visualization

3D Visualization Techniques:

- Surface Rendering
- Volume Rendering
- Isosurface Extraction
- 3D Slice Stacks

Concatenated or Reconstructed image can be visualized in 3D image using Iso surface shown in fig 4.21.



(a) Iso surface 3D visualization (b) Faces and Vertices Representation Fig 4.21: 3D visualization using Iso surface

Tools and Software for Visualization:

- 3D Slicer
- ITK-SNAP
- OsiriX
- ImageJ/FIJI
- MATLAB
- Python Libraries (SimpleITK, PyRadiomics, PyVista)

VIII. INTEGRATION AND PERFORMANCE EVALUATION

Integration of Segmentation and Classification Methods: Combining segmentation and classification techniques provides a comprehensive analysis of ICH, aiding in accurate diagnosis and treatment planning.

Evaluation of the Combined System's Performance: Metrics such as sensitivity, specificity, accuracy, and Dice similarity coefficient were used to evaluate the performance of the integrated system.

Comparative Analysis with Existing Approaches: The integrated system was compared with traditional ML and DL methods, highlighting its advancements and potential clinical impact.

Scatter plot is a graphical representation as well as classification of two Features between two classes shown in Fig 4.17.

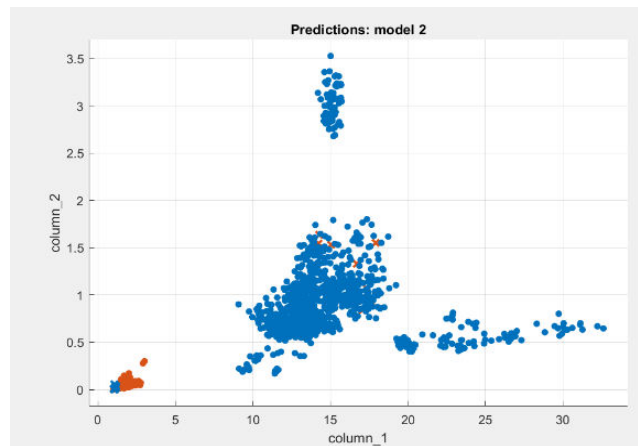


Fig 4.17 Scatter plot

Confusion matrix shown fig 4.18 is a performance measurement for Support Vector Machine Classifier where output can be two or more classes.

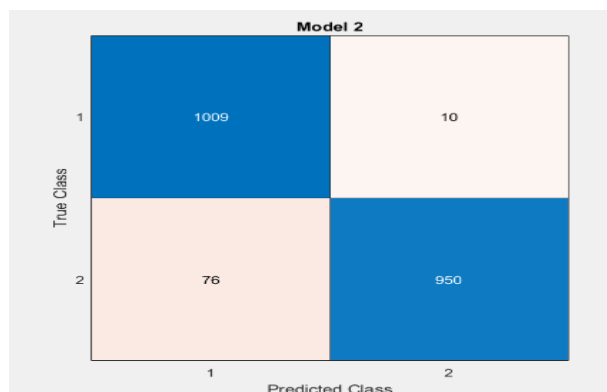


Fig 4.18: Confusion matrix

IX. CONCLUSION AND FUTURE WORK

The proposed system effectively segments, classifies, visualizes, and analyzes ICH in CT brain images, providing crucial information for clinical decision-making. Future work will focus on improving classification accuracy, handling multiple hemorrhages in a single slice, and enhancing 3D visualization for successful surgical procedures.

The future work would be to increase the accuracy of classification for accurate classified between normal brain and ICH brain. Need to improve ICH segmentation while multiple haemorrhage in single slice. Enhance the location of 3D ICH in all direction for implementing successful surgical procedure.

REFERENCES

1. Amelia, C., et al. (2017), 'Calculation of the cerebral haemorrhage volume using analysis of computed tomography image', *IJIRAE*, 4(6).
2. Chan, T. (2007), 'Computer aided detection of small acute intracranial haemorrhage on CT of brain', *Computerized Medical Imaging and Graphics*, 285-298.
3. Dhawan, A.P., et al. (2007), 'Image analysis and 3-D visualization of intracerebral brain haemorrhage', *IEEE Symposium*, 140-145.
4. Guo, D., et al. (2020), 'Simultaneous Classification and Segmentation of Intracranial Haemorrhage Using a Fully Convolutional Neural Network', *ISBI*, 118-121.
5. Hu, K., et al. (2020), 'Automatic segmentation of intracerebral haemorrhage in CT images using encoder-decoder CNN', *Information Processing & Management*, 57(6), 102352.
6. Lee, T.H., et al. (2009), 'Segmentation of CT brain images using unsupervised clusterings', *Journal of visualization*, 131-138.
7. Ma, G.Q., et al. (2013), 'Optimization of k-means clustering Segmentation in Head CT images', *Applied Mechanics and Materials*, 411, 1247-1250.
8. Majumdar, A., et al. (2018), 'Detecting intracranial haemorrhage with deep learning', *IEEE Engineering in Medicine and Biology Society*, 583-587.
9. Patel, A., et al. (2019), 'Intracranial Haemorrhage Identification in 3D Non-Contrast CT', *IEEE Access*, 7, 92355-92364.
10. Qiu, Y., et al. (2019), 'Semantic Segmentation of Intracranial Haemorrhages in Head CT Scans', *ICSESS*, 112-115.
11. Rahmany, I., et al. (2014), 'Detection of intracranial aneurysm in angiographic images using fuzzy approaches', *International Image Processing, Applications and Systems Conference*, 1-6.
12. Sherekar, R.M., et al. (2014), 'Reconstruction of DICOM images for manufacturing of customized anatomical implants', *American Journal of Mechanical Engineering and Automation*, 1(5), 48-52.
13. Singh, P., et al. (2018), 'Haemorrhage segmentation by fuzzy c-mean with Modified Level Set on CT imaging', *SPIN*, 550-555.
14. Sumijan, M.S., et al. (2017), 'Hybrids Otsu method, feature region and mathematical morphology for calculating volume haemorrhage brain on CT- scan image and 3D reconstruction', *TELKOMNIKA*, 15(1), 283-291.



INTERNATIONAL
STANDARD
SERIAL
NUMBER
INDIA



INTERNATIONAL JOURNAL OF INNOVATIVE RESEARCH

IN SCIENCE | ENGINEERING | TECHNOLOGY

 9940 572 462  6381 907 438  ijirset@gmail.com



www.ijirset.com

Scan to save the contact details