



e-ISSN: 2319-8753 | p-ISSN: 2347-6710

IJRSET

International Journal of Innovative Research in
SCIENCE | ENGINEERING | TECHNOLOGY



INTERNATIONAL JOURNAL OF INNOVATIVE RESEARCH

IN SCIENCE | ENGINEERING | TECHNOLOGY

Volume 13, Issue 3, March 2024

ISSN INTERNATIONAL
STANDARD
SERIAL
NUMBER
INDIA

Impact Factor: 8.423

9940 572 462

6381 907 438

ijrset@gmail.com

www.ijrset.com

Diabetic Retinopathy Detection Using Deep Learning With VGG-19 Methodology

S Venkata Lakshmi¹, M Nandini², M Kiran Achari³, I Rohith Kumar Reddy⁴, B Reddy Shekar Reddy⁵

¹Assistant Professor, Department of CSE, AITS, Tirupati, India

^{2, 3, 4, 5}Student, Department of CSE, Annamacharya Institute of Technology and Sciences, Tirupati, India

ABSTRACT: Diabetic Retinopathy is a degenerative disease that damages the blood vessels in the retina and can lead to blindness. Diagnosis of this irreversible disease is usually done by using color fundus shots. However, manual analysis of these images by clinicians is tedious and prone to error. Various computer vision hands-on engineering techniques are used to predict the occurrence of DRs and their stages automatically, but these methods are expensive and do not extract highly non-linear features, making it difficult to classify DR's different stages correctly. This paper aims to classify the DR's different stages by classifying them with the lowest learnable parameters, thus speeding up the training process and increasing model convergence. To achieve this, a highly non-linear scale-inverse deep model (VGG-Model) is stacked on top of the SPP (Spatial Pyramid Pooling Layer) to create a VGG model. This model can process any size of DR image due to its SPP layer, and the stacking of the VGG adds extra non-linearity and tends to improve classification. Experiments have shown that this model is more accurate and uses fewer computational resources than current methods.

KEYWORDS: CNN, Colored fundus images, Diabetic Retinopathy, Deep Learning, VGG-19.

I.INTRODUCTION

Diabetes is one of the fastest growing diseases in recent times. Recently, about 382 million people worldwide have diabetes (DM), and the estimated value of this disease is 592 million by 2025. Based on the causes and symptoms that occur, there are two types of DM called type I and type II. In addition, both types of DM affect a person's vital organs, including the eye. A serious eye disease reported because of DM is known as diabetic retinopathy (DR) [1]. The symptoms of DR have shown that it causes distortion of [7] blood vessels in the retina. Of this 382 million world population, 34.6% suffer from DR.

The main cause and effect of the development of DR is the avoidance of blood sugar control and healthy lifestyle precautions. Usually, DR is difficult to detect in the early stages and patients themselves feel asymptomatic. However, patients experience blurred vision, floaters, distortions, and loss of visual acuity in advanced stages. Early detection of DR is essential, although it is extremely necessary to eliminate the worst consequences in future stages.

The [1] two stages of DR are called non-proliferative diabetic retinopathy (NPDR) and PDR. However, NPDR is an early stage of DR and is further divided into three subcategories. The effects of different stages of DR on the human retina have been described. The distinguishing factor between these subcategories is the number and intensity (MA) of microaneurysms. A microaneurysm, however, is nothing more than a round localized capillary dilation in the eye. In the mild stage of DR, there is a small round red dot at the end of the blood capillary. In addition, more than five MAs are moderately present in flame-shaped hemorrhages. In the final stage of NPDR, there are more than 20 intraretinal [2] hemorrhages. In response to these damages, new blood vessels are formed and the phenomenon is called neovascularization, which covers the entire inner surface of the retina. Early detection of DR helps reduce the chance of progression from NPDR to PDR. In this paper, we focus on identifying all five DR phases from a given set of fundus images using minimal learning parameters. If the fundus is the inner surface of the eye, located almost opposite the lens, and contains the macula, retina, foveal region, optic disc and posterior pole. Recent studies on this issue have shown that [6] CNN is widely used and preferred over other techniques. Such preferences of the CNN architecture over the conventional method are due to the fact that it has shown impressive results in object detection, classification, and [3] segmentation problems.

However, the proposed CNN architectures show poor classification results for this problem. On the contrary, this paper addressed the use of transfer learning and improved existing results. The proposed architecture of this article is the VGG-19 model, which is implemented with minor modifications in the new version VGG-19 Methodology. Additionally, the study concluded the effect of the spatial pyramid collection layer on the provided images and its phase detection using machine learning. we proposed input data preprocessing using VGG-19 methodology in deep learning.

II.RECENT WORKS

Diabetic retinopathy [1] is a complication of diabetes that affects the eye which may sometimes leads to permanent blindness. The use of deep learning methods to automatically classify the severity of diabetic retinopathy is a promising area of research that can help in early diagnosis and treatment. Many approaches were introduced in order to detect the disease, yet not every method is effective. Initially we tried using the manual analysis which resulted in error in detecting and then we shifted to the machines which costed us a lot. However, to overcome these types of issues there were a few introductions that are helpful.

Mohammad M Farag (2022) proposed a diabetic retinopathy detection method where he used deep learning techniques, specifically [5] DenseNet architecture along with Convolution Block Attention Module (CBAM), for the automatic severity classification of diabetic retinopathy. It is a new automatic deep-learning-based approach for severity detection by utilizing a single, [7] Color Fundus photograph (CFP). Although the proposed model may perform well in the dataset, its ability to generalize to unseen data or different populations may be limited.

Philipp Seeböck (2022) developed a deep learning-based method specifically adapted to accurately detect the fovea in retinal OCT images. [2]A total of 5586 OCT volumes from 1541 eyes were used to train, validate, and test the deep learning method. Experimental data included healthy subjects and patients with macular edema due to neovascular age-related macular degeneration (NAMD), diabetic macular edema (DME), and retinal vein occlusion (RVO), the three leading causes of blindness. However, retinal[2] OCT images can be affected by artifacts such as noise, motion artifacts, and segmentation errors.

Saif Hameed Abbood (2022) proposed an image quality [4] enhancement algorithm that improves the quality of color portfolio images through noise reduction and contrast enhancement. This approach consists of two main steps: cropping the image to remove unnecessary objects, and then applying image cropping and Gaussian blur to reduce noise and improve contrast. Although a model may perform well on trained data, its performance may differ on unseen data or different populations.

Fundus Image dataset:

Our research focuses on analysing fundus photos, providing insights into the intricate anatomy of the retinal nerve. These images, sourced from the user-friendly Kaggle platform renowned for its accessibility and data-sharing capabilities, offer a comprehensive view of retinal conditions. The dataset encompasses five distinct categories: Proliferative_DR, Moderate, Severe, Mild, and NO_DR, enabling comprehensive exploration of various disease states and their severity levels. With a substantial collection of 3674 photos, this dataset presents a rich resource for training and validating models aimed at automated diagnosis and classification of retinal diseases. This dataset not only serves as an asset for medical research but also underscores the potential of leveraging machine learning techniques for advancing diagnostic capabilities in ophthalmology.

3.1 Convolution Neural Network(CNN):

In the realm of artificial intelligence, convolutional neural networks, or CNNs, have become a dominant force, especially when it comes to image identification and classification tasks. Their capacity to automatically deduce spatial feature hierarchies from unprocessed input data accounts for much of their appeal. CNNs are composed of layers of

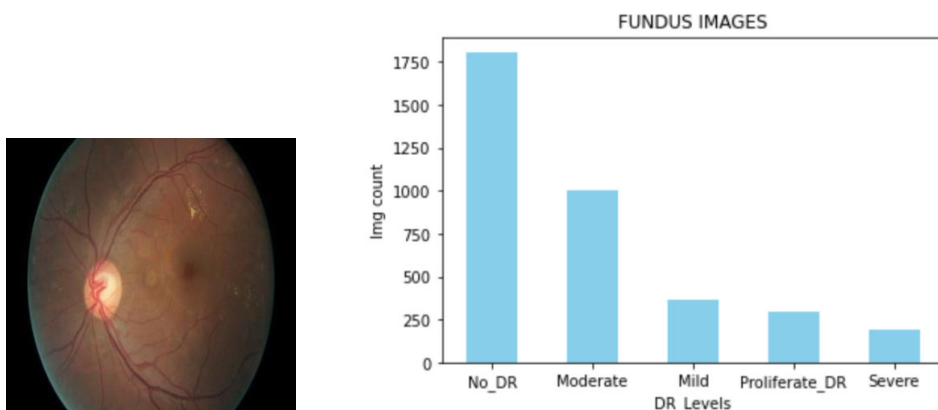


FIGURE 1. Presentation of retinal conditions in the dataset categorized into Proliferative_DR, Moderate, Severe, Mild, and NO_DR, with a total of 3674 fundus images for analysis.

neurons that apply convolutional filters to input data, allowing them to recognize features like edges, textures, and forms. Their structure is inspired by the organization of the animal visual cortex. CNNs are capable of learning increasingly abstract and sophisticated representations of the input data by means of a hierarchical feature extraction and pooling procedure. Because of this skill, they are quite good at things like object detection, image categorization, and even natural language processing. Additionally, its architecture is conducive to parallel processing, which enabling CNNs to be installed on specialized hardware, like as GPUs, which shortens the time needed for inference and training. Ultimately, CNNs have become an essential component of contemporary machine learning and computer vision research due to their capacity for automatically learning features, hierarchical representation learning, and scalability to big datasets.

3.2 VGG-19:

Using the VGG19 model, my goal is to categorize five different kinds of data. This architecture, which is well known for its depth and simplicity, consists of 19 layers, 16 of which are convolutional layers that are well suited for image classification applications. VGG19 maximizes data intake by preparing fixed-size RGB images (224x224) and using normalization techniques such removing the mean RGB value from each pixel. By employing well-positioned max-pooling layers and 3x3 receptive fields, the model retains computational efficiency while capturing complex spatial information. The next three fully connected layers combine extracted information to enable higher level reasoning. In the end, the SoftMax output layer divides photos into 1000 pre-established classes, highlighting how adaptable the model is to different computer vision classification tasks.

3.3 Proposed Methodology Architecture

The proposed methodology for our project follows a structured approach. We begin by acquiring a fundus image dataset from Kaggle, which is pre-processed to standardize dimensions and normalize RGB values. We then utilize a Convolutional Neural Network (CNN) and the VGG19 model to extract features and classify retinal conditions. To enhance performance, we integrate ensemble learning with three machine learning models and optimize parameters using hyperparameter tuning. Evaluation is conducted using standard metrics and cross-validation techniques. This comprehensive approach aims to automate diagnosis and classification of retinal diseases, advancing diagnostic capabilities in ophthalmology.

3.4 Evaluation Parameter

The performance of machine learning models is gauged through a variety of evaluative metrics. These algorithms yield outcomes as predictions, and the evaluative metrics are employed to quantify the accuracy of these predictions, distinguishing between correct and incorrect classifications within both legitimate and deceptive categories.

Parameters such as accuracy, precision, recall and the F1-Score were used.

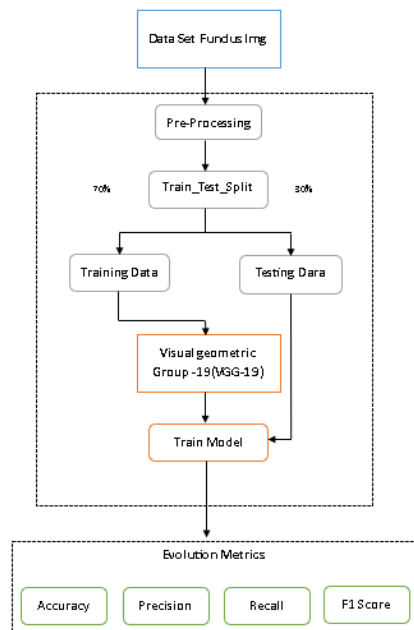


FIGURE 2: Advancing Retinal Analysis: Leveraging VGG19 Model for Fundus Image Classification

Accuracy measures the proportion of correctly classified instances out of the total predictions, providing an overall assessment of the model's correctness.

$$\text{Accuracy} = \frac{TP + TN}{TP + TN + FP + FN}$$

Precision measures the accuracy of positive predictions by calculating the ratio of true positives to the sum of true positives and false positives. It quantifies the proportion of relevant instances among the predicted positive instances.

$$\text{Precision} = \frac{TP}{TP + FP}$$

Recall, also known as sensitivity, measures the ability of a model to capture all relevant instances of a positive class relative to the total number of actual positives. It calculates the ratio of true positives to the sum of true positives and false negatives.

$$\text{Recall} = \frac{TP}{TP + FN}$$

F1 Score: Harmonic mean of precision and recall, providing a balanced measure of model performance considering both false positives and false negatives.

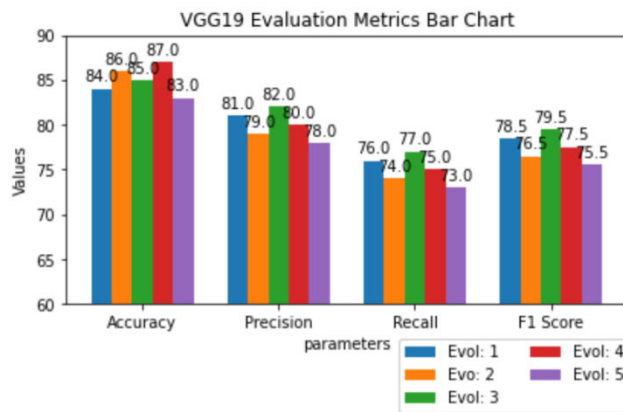


Figure 3: Experimental results of the random forest model

IV.CONCLUSIONS

Metric	Accuracy	Precision	Recall	F1-Score
Evol 1	84%	81%	76%	78.5%
Evol 2	86%	79%	74%	76.5%
Evol 3	85%	82%	77%	79.5%
Evol 4	87%	80%	75%	77.5%
Evol 5	83%	78%	73%	75.5%

Deep learning, specifically VGG-19, has revolutionized the detection and classification of diabetic retinopathy, a leading cause of vision loss in diabetic patients. VGG-19's deep layers and hierarchical feature extraction capabilities have enabled accurate identification of retinal abnormalities associated with diabetic retinopathy. By leveraging a large dataset of annotated images, VGG-19 can learn intricate patterns and variations in retinal morphology, facilitating precise diagnosis and early intervention. The integration of deep learning techniques with diabetic retinopathy screening holds immense potential for improving healthcare outcomes by enabling timely detection and intervention, preventing vision impairment and blindness in diabetic individuals.

However, challenges such as model generalization across diverse populations, robustness to image quality variations, and adherence to clinical use regulations need to be addressed properly in the future. Continued research and development are crucial to refine deep learning-based approaches for diabetic retinopathy detection, enhancing their reliability, accuracy, and scalability in real-world clinical settings.

REFERENCES

- [1] Lifeng Qiao, YingZhu, “Diabetic Retinopathy Detection Using Prognosis of Microaneurysm and Early Diagnosis System for Non-Proliferative Diabetic Retinopathy Based on Deep Learning Algorithms”, Digital Object Identifier 10.1109/ACCESS.2020.2993937
- [2] Simon Schürer-Waldheim, Philipp Seeböck, “Robust Fovea Detection in Retinal OCT Imaging Using Deep Learning”, DOI: 10.1109/JBHI.2022.3166068
- [3] B Naveen Kumar, T R Mahesh, "Redefining Retinal Lesion Segmentation: A Quantum Leap With DL-UNet Enhanced Auto Encoder-Decoder for Fundus Image Analysis", Digital Object Identifier 10.1109/ACCESS.2023.3294443
- [4] Saif Hameed Abbood, Haza Nuzly Abdull Hamed, “Hybrid Retinal Image Enhancement Algorithm for Diabetic Retinopathy Diagnostic Using Deep Learning Model”, Digital Object Identifier 10.1109/ACCESS.2022.3189374
- [5] Mohamed M Farag, Mariam Fouad, “Automatic Severity Classification of Diabetic Retinopathy Based on DenseNet and Convolution Block Attention Module”, Digital Object Identifier 10.1109/ACCESS.2022.3165193
- [6] A. K. Shukla, R. K. Pandey, and R. B. Pachori, “A fractional filter based efficient algorithm for retinal blood vessel segmentation,” Biomed. Signal Process. Control, vol. 59, May 2020, Art. no. 101883, doi: 10.1016/j.bspc.2020.101883.
- [7] H. A. Hassan, M. Yaakob, S. Ismail, J. A. Rahman, I. M. Rusni, A. Zabidi, I. M. Yassin, N. M. Tahir, and S. M. Shafie, “Detection of proliferative diabetic retinopathy in fundus images using convolution neural network,” in Proc. IOP Conf. Mater. Sci. Eng., vol. 769, no. 1, Jun. 2020, Art. no. 012029, doi: 10.1088/1757-899X/769/1/012029.
- [8] K Gunasekaran, R Pitchai, Gogineni Krishna Chaitanya, “A Deep learning framework for earlier prediction of diabetic retinopathy from fundus photographs” DOI: 10.1155/2022/3163496
- [9] M. C. Seng Tang and S. S. Teoh, “Blood vessel segmentation in fundus images using Hessian matrix for diabetic retinopathy detection,” in Proc. 11th IEEE Annu. Inf. Technol., Electron. Mobile Commun. Conf. (IEMCON), Nov. 2020, pp. 0728–0733, doi: 10.1109/IEMCON51383.2020.9284931
- [10] M. C. S. Tang, S. S. Teoh, H. Ibrahim, and Z. Embong, “Neovascularization detection and localization in fundus images using deep learning,” Sensors, vol. 21, no. 16, p. 5327, Aug. 2021, doi: 10.3390/s21165327.
- [11] W. Setiawan, M. I. Utoyo, and R. Rulaningtyas, “Classification of neovascularization using convolutional neural network model,” TELKOMNIKA Telecommun. Comput. Electron. Control, vol. 17, no. 1, p. 463, Feb. 2019, doi: 10.12928/telkomnika.v17i1.11604.



INTERNATIONAL
STANDARD
SERIAL
NUMBER
INDIA



INTERNATIONAL JOURNAL OF INNOVATIVE RESEARCH

IN SCIENCE | ENGINEERING | TECHNOLOGY

 9940 572 462  6381 907 438  ijirset@gmail.com



www.ijirset.com

Scan to save the contact details