



e-ISSN: 2319-8753 | p-ISSN: 2347-6710

# IJIRSET

International Journal of Innovative Research in  
**SCIENCE | ENGINEERING | TECHNOLOGY**



# INTERNATIONAL JOURNAL OF INNOVATIVE RESEARCH

IN SCIENCE | ENGINEERING | TECHNOLOGY

Volume 13, Issue 11, November 2024

**ISSN** INTERNATIONAL  
STANDARD  
SERIAL  
NUMBER  
INDIA

**Impact Factor: 8.524**

 9940 572 462

 6381 907 438

 [ijirset@gmail.com](mailto:ijirset@gmail.com)

 [www.ijirset.com](http://www.ijirset.com)

# Brain Tumor Localization using Image Processing Techniques

Harish G S, Shubha N C, Thanushree P, Mahalakshmi N, Yashaswini T A

Assistant Professor, Department of ISE, CIT, Gubbi, Tumkur, Karnataka, India

UG Student, Department of ISE, CIT, Gubbi, Tumkur, Karnataka, India

**ABSTRACT:** A brain tumor is an abnormal growth of tissue that develops within the brain or its surrounding areas. There are three main types of brain tumors: Glioma, Meningioma, and Pituitary, categorized based on their origin. To accurately diagnose these tumors, it is essential to identify their location within the brain and surrounding structures. In this study, we utilized T1-weighted MR images in axial view for tumor detection. Various image processing techniques, including thresholding, area filtering, boundary tracing, region merging, and image subtraction, were employed to locate the tumor. For the experiment, 100 MR images were used for each tumor type (Glioma, Meningioma, and Pituitary), and the tumor was successfully detected in all cases.

**KEYWORDS:** Brain tumor, Tumor localization, image processing, MRI, Detection

## I. INTRODUCTION

The exact cause of brain tumors is still unknown, but they are often linked to symptoms such as seizures, headaches, motor weakness, nausea, and changes in vision. Among the most dangerous types of brain tumors are those that spread throughout the brain, called brain metastasis. The World Health Organization has identified around 130 different types of brain tumors, with gliomas, meningiomas, and pituitary tumors being the most common. Brain tumors are usually detected through imaging methods like CT scans or MRIs, and a biopsy is performed to check whether the tumor is cancerous. Brain tumors are classified based on where they originate: gliomas come from brain tissue, meningiomas from the protective layers around the brain (dura mater), and pituitary adenomas from the pituitary gland. Figure 1 shows examples of T1-weighted MRI scans of the brain in axial view. MRI-based computer-aided diagnosis is increasingly used because it is non-invasive, does not harm the tissue, and provides flexible, detailed images of the brain [1]. MRI scans, including T1-weighted, T2-weighted, and FLAIR sequences, offer high-resolution images of soft tissues, which are essential for diagnosing brain disorders. MRI can create detailed cross-sectional images from different angles—axial, coronal, and sagittal—each providing a different view of the brain. However, identifying and locating brain tumors from MRI slices remains a challenging task. Many researchers have explored ways to improve the detection and segmentation of brain tumors. Chalsuparp et al. developed a method to extract brain tissue from axial T1-weighted MRI images by focusing on areas with similar intensities between brain and non-brain regions. Their approach had four steps: thresholding to create a binary image, morphology erosion to separate touching objects, component labeling to identify brain regions, and dilation with region filling to enhance the image and restore missing details. However, this method struggles when brain tissue is in close contact with the skull. [2]. Santosh et al. used thresholding combined with edge detection techniques, like the Sobel operator, to effectively detect brain tumors and outline their boundaries. They also estimated the tumor area to determine the stage of the disease [3]. Similarly, Manisha et al. used edge detection and thresholding to automate brain tumor detection, achieving accurate results with a median filter and Sobel edge detector, which efficiently highlighted the tumor borders [4]. Zaw et al. proposed a method for detecting brain tumors in MRIs using Naive Bayes classification and maximum entropy thresholding, applied to the REMBRANDT dataset. Their method achieved an 81.25% detection rate for tumor images, with an overall accuracy of 94%. This approach was effective in detecting tumors in various brain regions, including the temporal lobe, although there were some false positives [5]. Suresha et al. combined K-means clustering and Support Vector Machines (SVM) for brain tumor detection. They used K-means to group the features extracted from MRI images, and then applied SVM classification to identify any abnormalities in the images [6]. Oniza and Kailash used edge detection to locate tumor regions in the brain. Their process included smoothing, gradient search, non-maximum suppression, double thresholding, and edge tracking to accurately detect the tumor boundaries. They also applied the LMS and Crammer rule to capture the shape of the tumor [7]. Tonmoy Hossain et al. explored machine learning techniques to detect brain tumors by distinguishing normal and abnormal brain tissue based on texture and statistical

features. They used Fuzzy C-Means clustering for tumor segmentation and applied machine learning models and Convolutional Neural Networks (CNN) for classification. However, handling large datasets proved to be challenging for this approach [8]. Debapriya Hazra and Yungcheol Byun proposed an algorithm combining skull stripping and U-Net segmentation for tumor detection, achieving a high detection accuracy of 93% on 3000 MRIs [9]. Additionally, deep learning-based methods have become more popular in recent years, showing promising results in brain tumor detection [10-12]. These studies highlight the significant progress made in detecting and segmenting brain tumors using MRI scans and computational techniques. Despite these advances, challenges remain in achieving consistent accuracy across diverse datasets and accurately locating tumors within the complex structures of the brain.

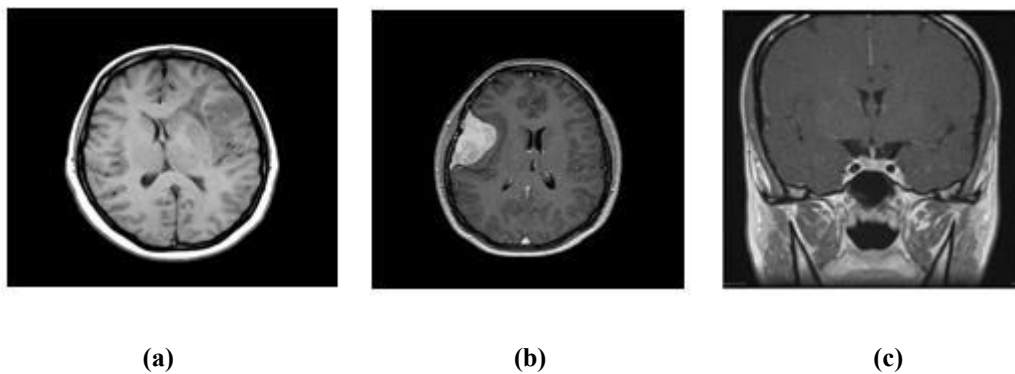


Fig.1. Samples of T1 weighted axial views Brain MRI. (a) Glioma  
(B)Meningioma (C) Pituitar

## II. LITERATURE SURVEY

Many image processing techniques have been explored to locate brain tumors in MRI scans, particularly for common types like glioma, meningioma, and pituitary tumors. Traditional methods often rely on thresholding, edge detection, and region segmentation to separate the tumor from healthy brain tissue. For example, Santosh et al. and Manisha et al. used Sobel edge detection and thresholding to outline tumor boundaries and assess their stage. Other techniques, such as Naïve Bayes classification and K-means clustering, have also been used to improve detection accuracy, with researchers like Zaw et al. achieving significant success. In recent years, machine learning approaches, including convolutional neural networks (CNNs) and U-Net models, have further advanced tumor detection and segmentation. These modern techniques, demonstrated by Hazra and Byun, have significantly improved the precision of tumor identification, even in complex regions of the brain, helping doctors make more accurate diagnoses.

## III. METHODOLOGY

The proposed methodology is divided into two main stages: skull stripping and tumor localization. Skull stripping is a crucial first step, as the skull must be removed from the brain MRI before detecting the tumor. This is important because the tumor and skull have similar densities, making it easy to mistakenly identify the skull as the tumor. Additionally, the skull is a large structure, and separating it from other non-brain tissues that aren't relevant to tumor detection can be challenging. The overall process flow of this methodology is shown in the diagram.

Each step of the methodology is outlined below:

- T1-weighted MRI images of the brain in axial view are used for tumor detection. The images have a resolution of 512x512 pixels and include three types of brain tumors: Glioma, Meningioma, and Pituitary tumors.
- The original MRI images are in RGB format (three color channels: Red, Green, and Blue). Since the MRI images are effectively grayscale (where the Red, Green, and Blue channels have the same values at each pixel), one of these channels can be extracted to create a single-channel grayscale image. In this case, the Green channel is selected for conversion.

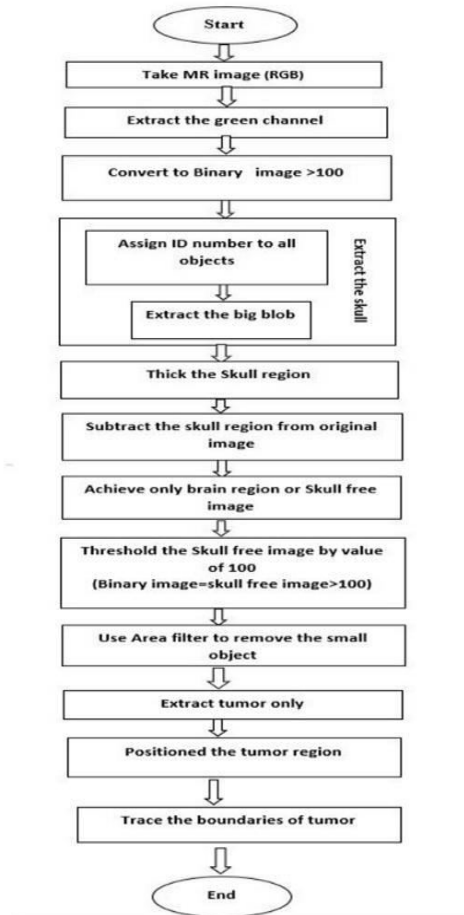


Fig 2. Workflow of the proposed methodology

- To create a binary image, a thresholding operation is applied to the grayscale image. Any pixel with a value above 100 is turned white, and any pixel below that value is turned black. This step helps simplify the image for further processing.
- After converting the image to binary, each distinct object in the image is assigned a unique ID number. The largest object, which is typically the skull, is identified and extracted.
- Once the skull region is identified, its thickness is increased using a specific operation (called  $eye(50)$ ). This step helps to remove any nearby high-density structures that are close to the skull but not part of the brain tissue.
- The thickened skull region is then subtracted from the original grayscale MRI image. The result is an image with the skull removed, leaving only the brain tissue for further analysis. This is referred to as the skull-free image.

From process executed from step 1 to step 6 is called skull stripping.

- The skull-free grayscale brain MRI image is then converted back into a binary image using the same threshold value of 100
- : An area filter is applied to the binary image to remove any small or irrelevant objects that are not part of the tumor, leaving only the potential tumor region.
- Finally, boundary tracing is performed to accurately outline the tumor within the original MRI image, helping to clearly identify its location and shape.

Steps 7 to 9 focus specifically on detecting and localizing the brain tumor.

#### IV. RESULT AND DISCUSSION

The proposed methodology was implemented using MATLAB 2021 and image processing tools. Three types of brain tumors—glioma, meningioma, and pituitary tumors—were tested. A total of 50 images of each tumor type were processed, and the methodology successfully removed the skull and localized the tumor in each case. Screenshots of each step in the process are shown in Fig. 3, Fig. 4, and Fig. 5.

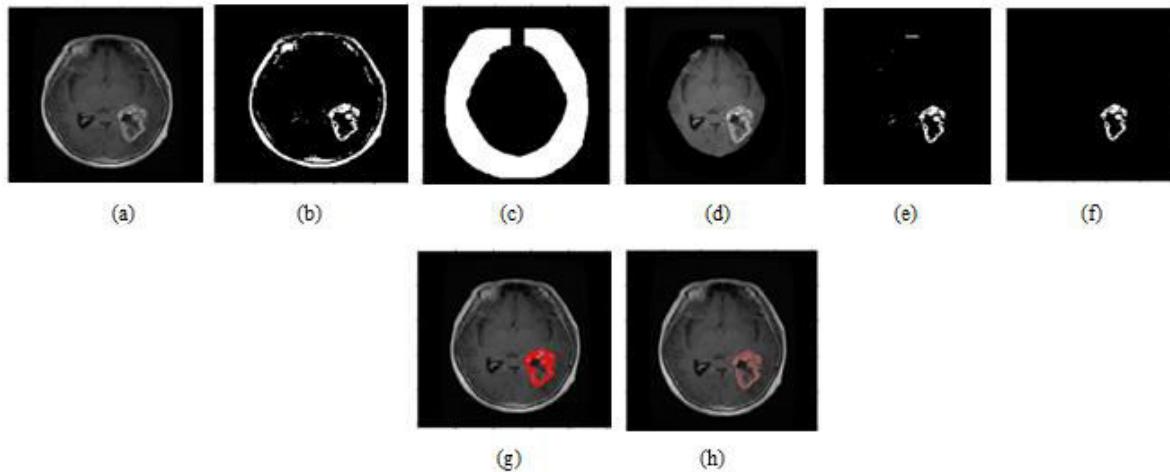


Fig.3. Brain Tumour localization in Glioma Brain MRI (a) Original MR Image, (b) Binarized image (c) skull region extracted, (d) skull free grayscale image, (e) Binarized image of skull free, (f) Tumour alone, (g) Tumour outlined in red in the overlay, (h) Tumour localized in original brain MRI with solid & tinted red in the overlay.

Fig. 3 shows the results of applying the methodology to a glioma brain MRI. The images in Fig. 3 represent the processed output at each step: Fig. 3(a): The original brain MRI. Fig. 3(b): The binarized image, where the image has been converted into black and white. Fig. 3(c): The skull region is extracted from the image. Fig. 3(d): The skull-free grayscale image, where the skull has been removed. Fig. 3(e): The binary image of the skull-free brain MRI. Fig. 3(f): The tumor alone, isolated from the rest of the image. Fig. 3(g): The tumor outlined in red within the image overlay. Fig. 3(h): The tumor localized in the original MRI, shown in solid red and tinted red in the overlay.

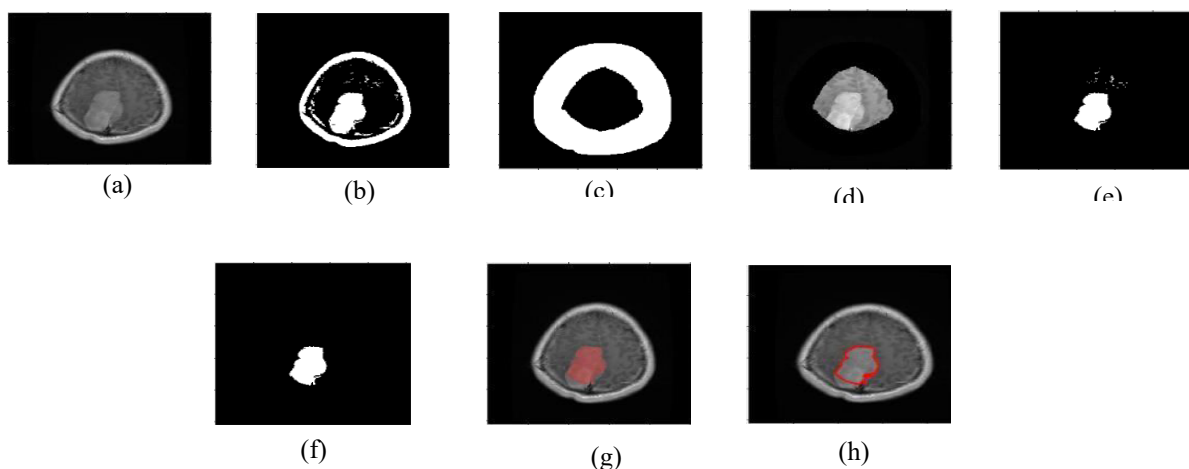


Fig. 4. Brain Tumour localization in meningioma Brain MRI (a) Original MR Image, (b) Binarized image (c) skull region extracted, (d) skull free grayscale image, (e) Binarized image of skull free, (f) Tumour alone, (g) Tumour outlined in red in the overlay, (h) Tumour localized in original brain MRI with solid & tinted red in the overlay.

Fig. 4 demonstrates the results of each step in the methodology applied to a glioma brain MRI. The images in Fig. 4 show the progression of the process: Fig. 4(a): The original MRI image of the brain. Fig. 4(b): The image after thresholding, resulting in a binarized image (black and white). Fig. 4(c): The skull region has been extracted from the image. Fig. 4(d): The image with the skull removed, leaving only the brain tissue in grayscale. Fig. 4(e): The skull-free image is then converted to binary format again. Fig. 4(f): The tumor region is isolated, showing only the tumor. Fig. 4(g): The tumor is outlined in red on top of the processed image. Fig. 4(h): The final result, where the tumor is localized in the original MRI image, highlighted in solid red and tinted red in the overlay.

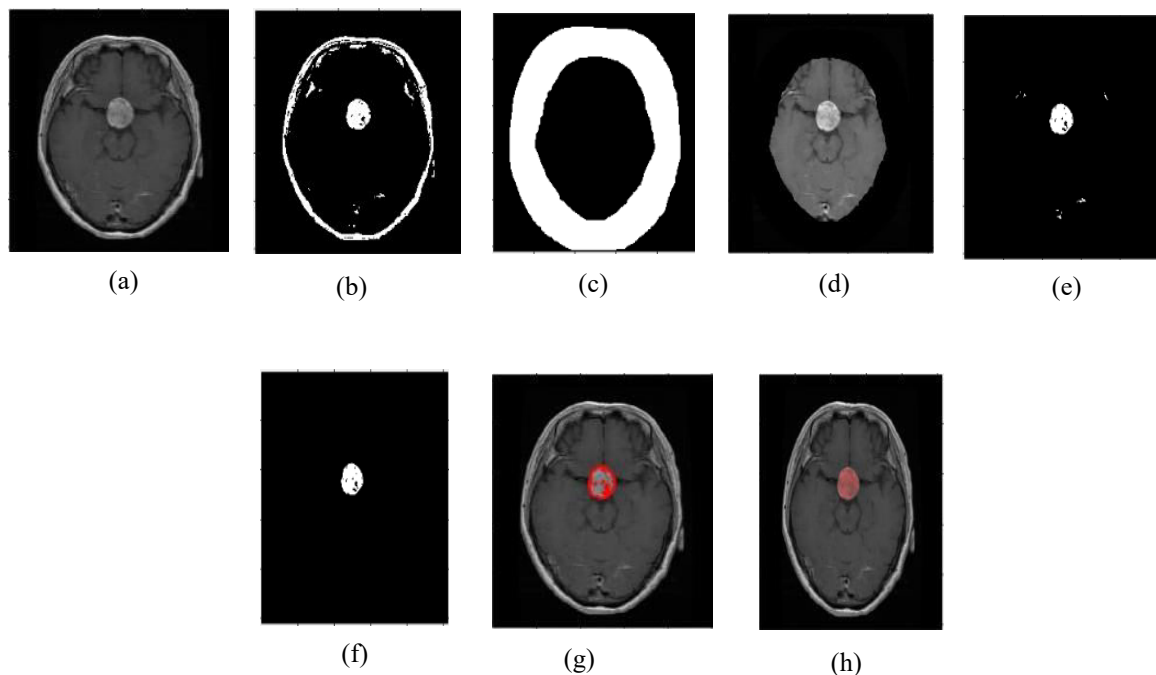


Fig.5. Brain Tumour localization in pituitary Brain MRI (a) Original MR Image, (b) Binarized image (c) skull region extracted, (d) skull free grayscale image, (e) Binarized image of skull free, (f) Tumour alone, (g) Tumour outlined in red in the overlay, (h) Tumour localized in original brain MRI with solid & tinted red in the overlay.

Fig. 5 shows the results of applying each step of the methodology to a glioma brain MRI. The images in Fig. 5 represent the following stages of the process: Fig. 5(a): The original MRI image of the brain. Fig. 5(b): The image after binarization, where it is converted into a black-and-white format. Fig. 5(c): The skull region is extracted and removed from the image. Fig. 5(d): The skull-free grayscale image, where the skull has been successfully removed, leaving only the brain tissue. Fig. 5(e): The binary image of the skull-free brain, converted back into black-and-white. Fig. 5(f): The tumor region isolated, showing only the tumor. Fig. 5(g): The tumor outlined in red on the processed image. Fig. 5(h): The final image, where the tumor is localized in the original MRI and highlighted in solid red and tinted red in the overlay.

### V. CONCLUSION

This paper presents a methodology for detecting the position of tumors in brain MRIs. The approach successfully identifies three types of brain tumors—glioma, meningioma, and pituitary tumors. The study focuses on T1-weighted axial view MRI images. In the future, the tumor localization process could be extended to other MRI sequences, such as T2-weighted and FLAIR, and applied to different image views like coronal and sagittal. This method can be a valuable tool for medical professionals, aiding in the accurate detection of tumor locations, which can help guide timely and appropriate treatment to prevent complication

**REFERENCES**

- [1] Kalavathi, P., Surya Prasath, V.B.: Methods on Skull Stripping of MRI Head Scan Images - a Review. *Advances in Pediatrics*. U.S.National Library of Medicine (2016).[www.ncbi.nlm.nih.gov/PMC/articles/PMC4879034](http://www.ncbi.nlm.nih.gov/PMC/articles/PMC4879034)
- [2] M. Chansuparp, A. Rodtook, S. Rasmeequan, and K. Chinnasarn, "The automated skull stripping of brain magnetic resonance images using the integrated method," 2015 8th Biomedical Engineering International Conference (BMEiCON), 2015, pp. 1-5, DOI: 10.1109/BMEiCON.2015.7399548.
- [3] S. S. Hunnur, A. Raut and S. Kulkarni, "Implementation of image processing for detection of brain tumors," 2017 International Conference on Computing Methodologies and Communication (ICCMC), 2017, pp. 717-722, DOI: 10.1109/ICCMC.2017.8282559.
- [4] Technologies (ICCPCT), 2017, pp. 1-5, Manisha, B. Radhakrishnan, and L. P. Suresh, "Tumor region extraction using edge detection method in brain MRI images," 2017 International Conference on Circuit, Power and Computing DOI: 10.1109/ICCPCT.2017.8074326.
- [5] H. T. Zaw, N. Maneerat and K. Y. Win, "Brain tumor detection based on Naïve Bayes Classification," 2019 5th International Conference on Engineering, Applied Sciences and Technology (ICEAST), 2019, pp. 1-4, DOI: 10.1109/ICEAST.2019.8802562
- [6] D. Suresha, N. Jagadisha, H. S. Shrisha, and K. S. Kaushik, "Detection of Brain Tumor Using Image Processing," 2020 Fourth International Conference on Computing Methodologies and Communication (ICCMC), 2020, 844-848, DOI:10.1109/ICCMC48092.2020.ICCMC-000156.
- [7] Shaikh, O., Jadhao, K., & ARMIET, S. (2019). Tumor Region Extraction Using Edge Detection Method in Brain MRI Image. *International Journal of Engineering Applied Sciences and Technology*. Vol. 4, Issue 3, pp. 244-248.
- [8] T. Hossain, F. S. Shishir, M. Ashraf, M. A. Al Nasim, and F. Muhammad Shah, "Brain Tumor Detection Using Convolutional Neural Network," 2019 1st International Conference on Advances in Science, Engineering and Robotics Technology (ICASERT), 2019, pp.1-6, DOI: 10.1109/ICASERT.2019.8934561.
- [9] Hazra, D., & Byun, Y. (2020). Brain tumor detection using skull stripping and U-net architecture. *International Journal of Machine Learning and Computing*, 10(2), 400-405.
- [10] Bhandari, Abhishta, Jarrad Koppen, and Marc Agzarian. "Convolutional neural networks for brain tumor segmentation." *Insights into Imaging* 11.1 (2020): 1-9.
- [11] Malathi, M., and P. Sinthia. "Brain tumor segmentation using a convolutional neural network with the tensor flow." *Asian Pacific journal of cancer prevention: APJCP* 20.7 (2019): 2095
- [12] Mehta, Raghav, and Tal Arbel. "3D U-Net for brain tumor segmentation." *International MICCAI Brainlesion Workshop*. Springer, Cham, 2018.



INTERNATIONAL  
STANDARD  
SERIAL  
NUMBER  
INDIA



# INTERNATIONAL JOURNAL OF INNOVATIVE RESEARCH

IN SCIENCE | ENGINEERING | TECHNOLOGY

 9940 572 462  6381 907 438  [ijirset@gmail.com](mailto:ijirset@gmail.com)



[www.ijirset.com](http://www.ijirset.com)

Scan to save the contact details