



e-ISSN: 2319-8753 | p-ISSN: 2347-6710

IJIRSET

International Journal of Innovative Research in
SCIENCE | ENGINEERING | TECHNOLOGY

INTERNATIONAL JOURNAL OF INNOVATIVE RESEARCH

IN SCIENCE | ENGINEERING | TECHNOLOGY

Volume 13, Issue 10, October 2024

ISSN INTERNATIONAL
STANDARD
SERIAL
NUMBER
INDIA

Impact Factor: 8.524

9940 572 462

6381 907 438

ijirset@gmail.com

www.ijirset.com

Detection of Hemorrhage for Fundus Images

Saurabh Chavanke, Sachin Avhad, Ketan Aher, Utkarsha Shinde

Prof. Sunil M. Kale

Department of Computer Engineering, Sandip Institute of Technology and Research Centre, Nashik, India

ABSTRACT: This paper presents a comprehensive study on the automated detection of diabetic retinopathy, a retinal disease commonly caused by diabetes that, if left untreated, can lead to blindness. The focus is on identifying hemorrhages, one of the early symptoms of diabetic retinopathy, using computerized techniques. The study analyzes 7,571 hemorrhage blobs extracted from 20 fundus images from the DIARETDB1 dataset. The methodology includes preprocessing by extracting the green channel, inverting the image, and applying Contrast Limited Adaptive Histogram Equalization (CLAHE). Morphological top-hat filtering is then used to isolate hemorrhage candidates, followed by rule-based classification based on features like compactness, area, and eccentricity. The proposed approach achieves a sensitivity of 80.37%, specificity of 99.53%, and an overall accuracy of 99.12%. This work contributes to the advancement of automated diabetic retinopathy detection, offering valuable insights for medical research and clinical applications..

KEYWORDS: Diabetic Retinopathy, Fundus Image, Hemorrhage, Image Processing, Red Lesion

I. INTRODUCTION

Diabetic Retinopathy (DR) is a serious complication of diabetes that affects the eyes and is one of the leading causes of vision impairment and blindness globally. Over the past decade, approximately 80% of patients who have lived with diabetes for more than ten years have also developed some form of DR. This condition contributes to 4.8% of all cases of blindness worldwide, making it a significant public health concern. DR refers to a group of eye diseases caused by damage to the retina—the light-sensitive tissue at the back of the eye responsible for sending visual information to the brain. As the retina is critical for sight, any damage can progressively lead to vision loss. The severity of DR is closely linked to how long a person has had diabetes. In its most severe form, if left undetected or untreated, DR can result in permanent blindness.

DR progresses through different stages, and its classification is generally divided into two main categories: Non-Proliferative Diabetic Retinopathy (NPDR) and Proliferative Diabetic Retinopathy (PDR). NPDR represents the early stage of the disease and is characterized by abnormalities in the retinal blood vessels, which may lead to leakage of blood or fluids into the retina. These leaks can manifest as hemorrhages, which are small red lesions that appear in the retinal tissue. Hemorrhages are often the earliest clinical indicators of DR, signaling the onset of more severe retinal damage. This stage is much more severe and significantly increases the risk of vision loss due to complications like retinal detachment and vitreous hemorrhage.

Early detection of hemorrhages is critical for diagnosing DR in its initial stages, which can greatly reduce the risk of further progression and vision loss. Identifying hemorrhages at an early stage enables timely medical intervention, which may include laser treatments or even surgery, helping to prevent irreversible damage. In traditional clinical settings, DR is diagnosed through the manual examination of retinal images captured using fundus cameras.

This paper focuses on a rule-based approach to detect hemorrhages in retinal fundus images as an early indicator of DR. Rule-based models are designed to classify features in images based on predefined rules or criteria. In this context, our system is designed to identify hemorrhages by applying a series of image processing steps followed by classification rules based on the physical characteristics of hemorrhages, such as shape, size, compactness, and color.

Rule-based models are advantageous in medical image analysis because they are interpretable, reliable, and easy to implement. They provide clear decision-making criteria, which is important for clinical settings where transparency and explanation of results are crucial. In this project, we have developed a rule-based model that achieves high accuracy, sensitivity, and specificity in detecting hemorrhages in fundus images, making it a valuable tool for early screening.

II. RELATED WORK

An efficient framework for the early diagnosis of DR diseases such as hemorrhages has been proposed in this paper. We have developed a new technique to detect and classify hemorrhages in retinal images. The proposed method consists four steps; (i) normal objects in retinal images are detected and masked because these objects have the same features with hemorrhages that lead to misdiagnosis. (ii) The dark regions are extracted by using adaptive thresholding and top-hat morphological techniques. (iii) Statistical and pattern recognition features are extracted from each region (iv) SVM is used to classify the candidate dark regions as either hemorrhages or healthy.[1]

There has been an increase in the use of digital image processing techniques for the screening of DR after it was recommended as one of the method for screening DR. Thus more work have been done to improve some of the existing screening methods while new approaches have also been introduced in order to increase the sensitivity and the specificity of the method. Sensitivity and specificity are the parameters used to measure the accuracy of an algorithm or a proposed diagnostic system. In this proposed work, Sensitivity refers to the percentage of abnormal fundus image classified as abnormal by the system while specificity can be defined as percentage of normal fundus image classified as normal. Abnormal image here means image with DR artifacts while normal means images without DR artifacts. The higher the values of these two factors the better is the system for the detection of DR. Most of the available work done can generally be categorized into screening of BDR and PDR while diagnosis of SDR has been left for the ophthalmologist. However, only few works have really been reported in the detection of Microaneurysm and exudates using geometric features of the artifacts. [2]

The proposed method is a result of the application of morphological operation together with rule-based classification. First, the fundus image is preprocessed and then the resulting image undergoes hemorrhage candidate extraction employing morphological top hat operation, and finally, rule-based classification is applied to classify the hemorrhage based on predefined features.[3]

The fundus images taken by the fundus cameras often have the problems of noises and non uniform illumination which usually make it complicated to extract the required features with similar intensity from the background. Therefore most of the times many image processing techniques are applied on the image to enhance its brightness and/or contrast so that feature extraction can be easily and effectively be implemented. [3]

Typically, fundus images are in RGB color space which consists of three color channels namely, red, green, and blue. Among these three, the green channel clearly exhibits the red color features of both hemorrhages and retinal blood vessels well when compared to other channels. Therefore, in the proposed method, green channel is extracted from the original fundus image at the start. The extracted green channel image now displays the hemorrhages and vessels in dark color of the gray scale. The image is then inverted in order to emphasize the areas of interest, the hemorrhages, in white. After that, Contrast Limited Adaptive Histogram Equalization (CLAHE) is applied to the image to increase its contrast. CLAHE will divide the image into smaller regions called tiles. On each of these tiles, equalization is applied to locally even out the distribution of gray-scale intensity, making use of the full range of the gray level value. This will expose the image with more uniformly distributed contrast and further emphasize some hidden features which were unclear before CLAHE was applied.[3]

The blobs obtained from the previous stage are analyzed to identify and extract features of each blob. Then the classification is done using rule based classification technique which works similar to if-then statement.

From a training set, a set of rules is generated, each containing a condition, which includes the conjunction of several feature tests, and a conclusion. From 4309 blobs generated from 12 fundus images in the training set, rules are devised for the purpose of classifying the hemorrhages according to the shape of the blobs. The features that were used to classify are for instance, area, color, eccentricity and compactness of the blobs. The area is calculated from the number of pixels of each blob. In addition, the color of the blobs must be close to red which is the color of hemorrhage.[3]

Match filter based bilinear morphological top-hat transformation is performed using a linear structuring element to discern structure from unconnected circular objects. Feature vector consisting of size, shape, energy and intensity are analysed using region-growing algorithm to segment microaneurysms [2, 3]. Features such as size, shape, texture, edge energy, intensity and depth were obtained using hmaxima transform on which a multiple overlapping windows and

radon transform were implemented to segment dark objects from the fundus image to locate microaneurysms and haemorrhages [4]

III. METHODOLOGY

- **Preprocessing:** Fundus images often have noise and uneven lighting, making feature detection difficult. To improve this, the green channel, which best highlights hemorrhages and blood vessels, is extracted. The image is then inverted to make hemorrhages more visible, followed by applying CLAHE to enhance contrast and reveal hidden features more clearly.
- **Morphological top hat transform:** The morphological top-hat transform helps extract small objects from an image. There are two types: white top-hat (difference between the image and its opened version) and black top-hat (difference between the image and its closed version). In this method, the white top-hat transform is applied to highlight small, bright features. After filtering the background with a ball-shaped element, the image is binarized, showing blood vessels and hemorrhages as white blobs. A median filter is then applied to reduce noise and further enhance the image.
- **Blob Analysis:** The blobs obtained from the previous stage are analyzed to identify and extract features of each blob. From a training set, a set of rules is generated, each containing a condition, which includes the conjunction of several feature tests, and a conclusion. From 4309 blobs generated from 12 fundus images in the training set, rules are devised for the purpose of classifying the hemorrhages according to the shape of the blobs. The features that were used to classify are for instance, area, color, eccentricity and compactness of the blobs. The area is calculated from the number of pixels of each blob. In addition, the color of the blobs must be close to red which is the color of hemorrhage.
- **Hemorrhage Classification:** A rule-based classification is used, working like "if-then" statements. From the training data, rules are created to classify blobs as hemorrhages based on these features. Round hemorrhages are identified by a compactness close to 1 and an eccentricity close to 0, while slim hemorrhages have a lower compactness and higher eccentricity. If a blob meets all the rule conditions, it's classified as a hemorrhage. The final image highlights the blobs that are likely hemorrhages.
- **Evaluation Metrics:** To evaluate the proposed method and compare it with others, the paper uses three key measures: sensitivity, specificity, and accuracy.

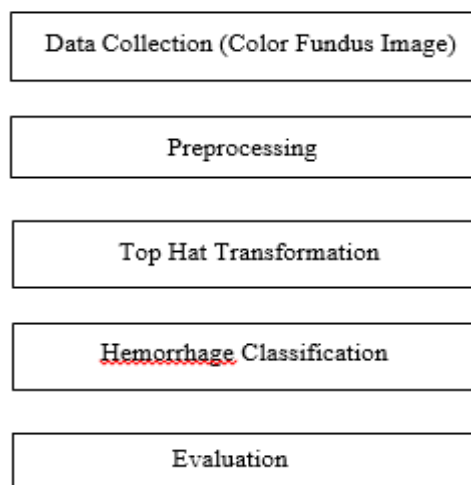
Sensitivity measures how well the method correctly detects positive cases (hemorrhages).

Specificity measures how well it correctly detects negative cases (non-hemorrhages).

Accuracy shows the proportion of all correctly detected pixels (positive and negative) out of the total pixels.

The evaluation compares each pixel in the detection result to the ground truth image, calculating the number of true positives (TP), true negatives (TN), false positives (FP), and false negatives (FN). These values are then used to calculate sensitivity, specificity, and accuracy.

3.1 Implementation Plan



IV. APPLICATIONS AND USE CASES

- **Early Diagnosis of Diabetic Retinopathy (DR):** Detects hemorrhages as early signs of DR, enabling timely medical intervention to prevent vision loss.
- **Screening for Diabetic Retinopathy in Large Populations:** Automated hemorrhage detection can help screen large numbers of patients quickly, reducing the burden on ophthalmologists.
- **Monitoring Disease Progression:** Helps track the progression of DR by detecting changes in the number or severity of hemorrhages over time.
- **Assisting Ophthalmologists in Clinical Decision Making:** Provides decision support by highlighting areas with hemorrhages, aiding specialists in diagnosis and treatment planning.
- **Telemedicine and Remote Diagnosis:** Enables remote screening and diagnosis in regions with limited access to healthcare, making it useful for telemedicine applications.
- **Research and Clinical Studies:** Assists in large-scale research by automating the detection of hemorrhages, enabling the study of DR patterns and treatment outcomes.
- **Personalized Treatment Planning:** Detection systems can help personalize treatments by analyzing the severity of retinal hemorrhages and guiding intervention plans.
- **Integration in Automated Retinal Disease Screening Systems:** Hemorrhage detection is a key component of fully automated systems for diagnosing retinal diseases, improving the efficiency of eye care.
- **Screening for Other Retinal Disorders:** Apart from DR, hemorrhage detection may assist in diagnosing other conditions such as hypertensive retinopathy and retinal vein occlusion.

V. CONCLUSION

This paper provides a comprehensive review of the automated detection of hemorrhages in fundus images as an early indicator of diabetic retinopathy (DR). The proposed rule-based approach combines various image processing techniques such as green channel extraction, Contrast Limited Adaptive Histogram Equalization (CLAHE), and morphological top-hat transformation, followed by rule-based classification to accurately identify hemorrhages. The system achieved high accuracy, sensitivity, and specificity, making it a valuable tool for early detection and screening of DR.

Automated hemorrhage detection systems offer numerous benefits, including early diagnosis of DR, large-scale population screening, monitoring disease progression, and supporting clinical decision-making. Additionally, these systems are essential for telemedicine, research, personalized treatment planning, and integration into fully automated retinal disease screening solutions. By improving the efficiency of detecting retinal disorders like DR, hypertensive retinopathy, and retinal vein occlusion, these methods contribute significantly to advancing healthcare and preventing vision loss.

Future research could focus on enhancing the classification model, incorporating more advanced techniques like machine learning, and expanding the dataset to improve generalization and performance across diverse populations. The development of these systems will continue to play a critical role in reducing the global burden of diabetic retinopathy and other retinal diseases.

REFERENCES

- [1] Ghassan Ahmed Ali¹, Thamer Mitib Ahmad Al Sariera “Detection and Classification of Hemorrhages in Retinal Images” 1College of Computer Science and Information Systems, Najran University, Najran, 61441, Saudi Arabia,2022
- [2] Vasudevan Lakshminarayanan , Hoda Kheradfallah , Arya Sarkar and Janarthanam Jothi Balaji “Automated Detection and Diagnosis of Diabetic Retinopathy”, MDPI,2021
- [3] Nutnaree Kleawsirikul, Smith Gulati, and Bunyarit Uyyanonvara, “Automated Retinal Hemorrhage Detection Using Morphological Top Hat and Rule-based Classification.” International Conference on Computer Communication and Informatics (ICCCI), 2013.
- [4] Preethi Patil, Savita Sheelavant, “Detection and Classification of Microaneurysms and Haemorrhages from Fundus Images for Efficient Grading of Diabetic Retinopathy.” IEEE International Conference on Contemporary Computing

and Communication, 2018.

- [5] J. P. Bae, K. G. Kim, H. C. Kang, C. B. Jeong, K. H. Park et al., "A study on haemorrhage detection using hybrid method in fundus images," *Journal of Digital Imaging*, vol. 24, no. 3, pp. 394–404, 2011.
- [6] W. Zhou, C. Wu, D. Chen, Z. Wang and Y. Yi et al., "Automated detection of red lesions using superpixel multichannel multifeature," *Computational and Mathematical Methods in Medicine*, 2017.
- [7] A. R. Chowdhury, T. Chatterjee and S. Banerjee, "A random forest classifier-based approach in the detection of abnormalities in the retina," *Medical & Biological Engineering & Computing*, vol. 57, no. 1, pp. 193–20, 2019.
- [8] Y. Hatanaka, T. Nakagawa, Y. Hayashi, T. Hara and H. Fujita, "Improvement of automated detection method of hemorrhages in fundus images," in *2008 30th Annual Int. Conf. of the IEEE Engineering in Medicine and Biology Society, Vancouver, British Columbia, Canada*, pp. 5429–5432, 2008.
- [9] L. Tang, M. Niemeijer, J. Reinhardt, M. Garvin and M. Abramoff, "Splat feature classification with application retinal haemorrhage detection in fundus images," *IEEE Transactions on Medical Imaging*, vol. 32, no. 2, pp. 364–375, 2012.
- [10] J. I. Orlando, E. Prokofyeva, M. Del Fresno and M. B. Blaschko, "An ensemble deep learning based approach for red lesion detection in fundus images," *Computer Methods and Programs in Biomedicine*, vol. 153, pp. 115–127, 2018.
- [11] T. Aziz, A. E. Ilesanmi and C. Charoenlarnnopparut, "Efficient and accurate hemorrhages detection in retinal fundus images using smart window features," *Applied Sciences*, vol. 11, no. 14, pp. 6391, 2021.
- [12] S. Maqsood, R. Damaševičius and R. Maskeliūnas, "Hemorrhage detection based on 3D CNN deep learning framework and feature fusion for evaluating retinal abnormality in diabetic patients," *Sensors*, vol. 21, no. 11, 2021.
- [13] N. Asiri, M. Hussain, F. Al Adel and H. Aboalsamh, "A deep learning-based unified framework for red lesions detection on retinal fundus images," *arXiv preprint arXiv: 2109.05021*, 2021.
- [14] P. Khojasteh, B. Aliahmad and D. K. Kumar, "Fundus images analysis using deep features for detection of exudates, hemorrhages and micro-aneurysms," *BMC Ophthalmology*, vol. 18, no. 1, pp. 1–13, 2018.
- [15] Y. Huang, L. Lin, M. Li, J. Wu, P. Wang et al., "Automated hemorrhage detection from coarsely annotated fundus images in diabetic retinopathy," in *Proc. of the 2020 IEEE 17th Int. Symp. on Biomedical Imaging (ISBI)*, Iowa City, IA, USA, pp. 1369–1372, 2020.
- [16] T. M. Al Sariera, and L. Rangarajan, "Extraction of blood vessels in retina," *Journal of Information Technology Research (JITR)*, vol. 11, no. 4, pp. 122–13, 2018.
- [17] T. M. Al Sariera, L. Rangarajan and R. Amarnath, "Detection and classification of hard exudates in retinal image," *Journal of Intelligent & Fuzzy Systems*, vol. 38, no. 2, pp. 1943–194, 2020.
- [18] Dipankar Das, Deepak Ranjan Nayak, Ram B. Pachori, "AES-Net: An adapter and enhanced self-attention guided network for multi-stage glaucoma classification using fundus images" , *Image and Vision Computing (Elsevier)* Volume :146 // 2024 DOI: <https://doi.org/10.1016/j.imavis.2024.105042>
- [19] D. Das, D. R. Nayak, S. V. Bhandary, U. R. Acharya, "CDAM-Net: Channel Shuffle Dual Attention Based Multi-Scale CNN for Efficient Glaucoma Detection Using Fundus Images" , *Engineering Applications of Artificial Intelligence (Elsevier)*
- [20] D. Ioannou, W. Huda and A. F. Laine, "Circle recognition through a 2D hough transform and radius histogramming," *Image and Vision Computing*, vol. 17, no. 1, pp. 15–26, 1999.
- [21] S. C. Lee and Y. Wang, "A general algorithm of recognizing small, vague and imager-like objects in a nonuniformly illuminated medical diagnostic image," in *Conf. Record of Thirty-Second Asilomar Conf. on Signals, Systems and Computers*, Pacific Grove, CA, USA, pp. 941–943, 1998.
- [22] R. V. J. P. H. Kälviäinen and H. Uusitalo, "DIARETDB1 diabetic retinopathy database and evaluation protocol," in *Medical Image Understanding and Analysis*, vol. 2007, pp. 61, 2007.



INTERNATIONAL
STANDARD
SERIAL
NUMBER
INDIA



INTERNATIONAL JOURNAL OF INNOVATIVE RESEARCH

IN SCIENCE | ENGINEERING | TECHNOLOGY

 9940 572 462  6381 907 438  ijirset@gmail.com



www.ijirset.com

Scan to save the contact details