



e-ISSN: 2319-8753 | p-ISSN: 2347-6710

IJIRSET

International Journal of Innovative Research in
SCIENCE | ENGINEERING | TECHNOLOGY

INTERNATIONAL JOURNAL OF INNOVATIVE RESEARCH

IN SCIENCE | ENGINEERING | TECHNOLOGY

Volume 13, Issue 10, October 2024

ISSN INTERNATIONAL
STANDARD
SERIAL
NUMBER
INDIA

Impact Factor: 8.524

9940 572 462

6381 907 438

ijirset@gmail.com

www.ijirset.com

Comparative Study on Detecting Diabetic Retinopathy using CNN, Machine Learning, and AI-based Diagnostic Systems

Dr.C.Sunitha, Aakash.P, Sri Ramanaa.S, Ashwin.B

Associate Professor and Head, Department of Software Systems, Sri Krishna Arts and Science College, Coimbatore, Tamil Nadu, India

U.G. Student, Department of Software Systems, Sri Krishna Arts and Science College, Coimbatore, Tamil Nadu, India

U.G. Student, Department of Software Systems, Sri Krishna Arts and Science College, Coimbatore, Tamil Nadu, India

U.G. Student, Department of Software Systems, Sri Krishna Arts and Science College, Coimbatore, Tamil Nadu, India

ABSTRACT: Diabetic Retinopathy (DR) is a growing global cause of blindness, and early detection and intervention are crucial for improving patient outcomes. Advancements in Artificial Intelligence (AI), particularly deep learning and machine learning, have led to automated systems for DR screening and diagnosis, offering high accuracy and efficiency. This paper reviews AI-based approaches for DR detection, comparing a deep convolutional neural network(CNN) model with a hybrid machine learning model. While AI systems show promise, challenges like lack of standardized development criteria and application scope remain. The study emphasizes the potential of AI in transforming DR diagnosis and highlights ongoing improvements and integration into clinical practice as key future directions.

KEYWORDS: Artificial Intelligence, Deep Learning, Diabetic Retinopathy, Deep Convolutional Neural Networks, Screening, Machine Learning, Validation for Artificial Intelligence, KNN, SVM, Random Forest, Retinal Fungus Images.

I. INTRODUCTION

Diabetic Retinopathy (DR), a leading cause of blindness among working-age adults globally, affects the blood vessels in the retina and requires early detection to prevent severe vision impairment or blindness. Early intervention can slow disease progression, making treatment more effective and cost-efficient, often involving less invasive procedures like laser therapy or injections rather than advanced surgeries. Timely detection not only preserves vision but also enhances quality of life, enabling individuals to maintain independence and productivity. Additionally, early diagnosis reduces the healthcare burden by minimizing the need for intensive care in advanced cases. Imaging modalities like fundus photography, optical coherence tomography (OCT), fluorescein angiography, and AI-driven imaging play a crucial role in detecting and managing DR by providing detailed views of retinal changes.

Diabetic Retinopathy (DR) is a growing global concern, driven by factors like unhealthy diets, sedentary lifestyles, and aging populations, particularly as diabetes becomes more prevalent. Advances in diabetes management have extended lifespans, but this has also increased the likelihood of complications such as DR, especially in low- and middle-income countries where healthcare access and awareness are limited. Early detection is crucial for preventing disease progression, making scalable screening programs, including AI-driven fundus photography, vital for timely diagnosis and treatment. Advanced imaging techniques like Optical Coherence Tomography (OCT) and Fluorescein Angiography play a key role in precise diagnosis, enabling tailored treatments that improve outcomes and reduce vision loss. Accessibility and affordability are critical, particularly in resource-limited areas, where portable devices and AI-powered platforms can help bridge healthcare gaps. This study compares various DR detection methods, including Deep CNN, traditional machine learning techniques, and AI-based systems, to evaluate their accuracy, efficiency, and scalability, with the goal of identifying the most effective approach for early detection and improved disease management.

II. LITERATURE SURVEY

Traditional methods for diagnosing Diabetic Retinopathy (DR) include direct and indirect ophthalmoscopy fundus photography, and fluorescein angiography, each offering distinct advantages and limitations. Direct ophthalmoscopy allows ophthalmologists to examine the retina through a handheld device, though it has a limited field of view, while indirect ophthalmoscopy provides a wider perspective with a head-mounted device, making it ideal for viewing the peripheral retina. Both techniques are highly accurate but rely heavily on practitioner expertise, are subjective, and are time-consuming, often limiting access in areas with few trained professionals. Fundus photography captures high-resolution retinal images, creating a lasting record and providing a broad view for detecting DR signs, but it demands skilled interpretation and high-quality cameras, leading to time-intensive manual reviews that introduce variability in diagnoses. Fluorescein angiography, used primarily in advanced DR cases, involves injecting a fluorescent dye to visualize retinal blood flow and detect subtle vascular changes, offering detailed insights but requiring specialized equipment, training, and being invasive and costly, which reduces its viability for widespread screening.

Deep Convolutional Neural Networks (CNNs) are advanced deep learning models designed for visual data processing, revolutionizing image recognition by autonomously learning key features without manual extraction, enhancing image recognition accuracy. CNNs consist of several layers, starting with an input layer that receives pixel data, followed by convolutional layers that apply filters to detect image features across various regions. Stride and padding control filter movement, while ReLU activation introduces non-linearity. Pooling layers, like max pooling, reduce feature map dimensions while retaining key information, and fully connected layers flatten features into a single vector for final classification, with the softmax function generating probability distributions in classification tasks. CNNs are trained on labeled datasets, where backpropagation adjusts filter weights to minimize prediction errors. In Diabetic Retinopathy (DR) detection, CNNs preprocess retinal images with data augmentation and normalization to improve generalization, extract hierarchical features indicative of DR, and perform classification across DR stages in an end-to-end learning process, which is more efficient than traditional methods. CNN-based models exhibit high accuracy and sensitivity, often outperforming traditional methods, although their "black-box" nature limits interpretability, with tools like Grad-CAM offering some visualization of their focus. CNNs are increasingly deployed in clinical DR screening programs, especially in underserved regions, where they enable rapid, automated analysis of retinal images, supporting early detection and integration into telemedicine platforms for remote DR screening and diagnosis.

Traditional machine learning methods like Support Vector Machines (SVM), Random Forests, and k-Nearest Neighbors (k-NN) have long been used for diabetic retinopathy (DR) detection, relying on manually engineered features from retinal images. These methods are less computationally demanding than CNNs, but they require significant effort in feature extraction and selection, making them less scalable for large or complex datasets. Consequently, their accuracy and sensitivity are generally lower than CNNs, which limits their effectiveness in large-scale DR screening programs. Despite their interpretability and accessibility, particularly in smaller healthcare settings, traditional machine learning methods are outperformed by CNNs due to their limited capacity for detecting nuanced DR features. This disparity highlights the need for more advanced approaches, such as CNNs, to manage DR more effectively and facilitate early detection across a wider range of healthcare applications.

AI have transformed diabetic retinopathy (DR) detection by autonomously learning hierarchical features directly from retinal images, eliminating the need for manual feature engineering required in traditional machine learning methods. CNNs comprise multiple layers: convolutional layers to extract features, activation functions like ReLU for non-linearity, pooling layers to reduce spatial dimensions while retaining critical information, and fully connected layers for classification. With backpropagation fine-tuning the model weights, CNNs achieve high accuracy and sensitivity in DR detection, often surpassing traditional methods, especially on large datasets. In DR applications, CNNs preprocess images with data augmentation and normalization, improving generalization across different DR stages. Despite the "black-box" challenge, interpretability tools like Grad-CAM offer some insight into CNN decision-making, aiding their growing use in clinical DR screening programs, particularly in underserved regions where automated analysis supports rapid and scalable DR diagnosis.

III. METHODOLOGY

Diagnosing Diabetic Retinopathy (DR) traditionally relies on direct and indirect ophthalmoscopy, fundus photography, and fluorescein angiography, each requiring expert interpretation and specialized tools. Ophthalmoscopy provides real-time examination but depends on practitioner skill, limiting accessibility in underserved areas. Fundus photography captures detailed retinal images but requires careful analysis, introducing diagnostic variability. Fluorescein angiography, used for advanced cases, offers detailed vascular insights but is invasive and costly. Traditional machine learning methods like SVM, Random Forests, and k-NN use manually crafted features for DR detection but often fall short in accuracy and scalability for large datasets. By contrast, deep CNNs, comprising convolutional, pooling, and fully connected layers, autonomously extract features from retinal images, eliminating manual feature engineering. Though CNNs can lack interpretability, tools like Grad-CAM offer some transparency. Their high accuracy and sensitivity, especially in large datasets, make CNNs well-suited for scalable DR screening, enabling early diagnosis and improved accessibility in diverse healthcare settings.

IV. EXPERIMENTAL RESULTS

The study used the ICDRS scale to classify Diabetic Retinopathy (DR) stages, analyzing 1,533 internal fundus images and 1,200 external images from the MESSIDOR1 database, with high interobserver agreement (κ values of 0.95 and 0.96). AI performance showed strong accuracy, with a κ of 0.69 for detecting “any DR,” 97.7% sensitivity for sight-threatening DR (STDR), and an AUC of 0.991, though it tended to overclassify moderate NPDR as severe. The external set confirmed moderate agreement (κ of 91.67%) and 92.92% specificity for STDR, but minor cases and subtle signs, like microaneurysms, were sometimes misclassified, indicating that while AI shows promise for screening, refinement is needed for detecting mild DR cases.

The study used the ICDRS scale to classify Diabetic Retinopathy (DR) stages, analyzing 1,533 internal fundus images and 1,200 external images from the MESSIDOR1 database, with high interobserver agreement (κ values of 0.95 and 0.96). AI performance showed strong accuracy, with a κ of 0.69 for detecting “any DR,” 97.7% sensitivity for sight-threatening DR (STDR), and an AUC of 0.991, though it tended to overclassify moderate NPDR as severe. The external set confirmed moderate agreement (κ of 91.67%) and 92.92% specificity for STDR, but minor cases and subtle signs, like microaneurysms, were sometimes misclassified, indicating that while AI shows promise for screening, refinement is needed for detecting mild DR cases.

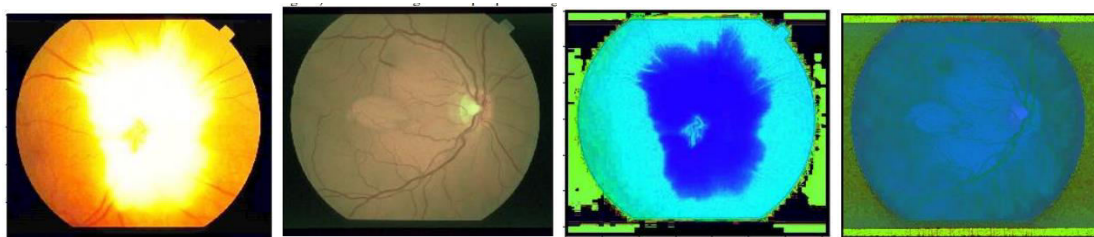


Fig.1(a)

Fig.1(b)

Fig.1(c)

Fig.1(d)



Fig.1(e)



Fig.1(f)

Fig. 1. Text Detection and Inpainting (a) Original image (b) Image after applying first set of criteria (c) Image after applying second set of criteria (d) Image mask (e) Inpainted image using patch size 4 x 4 and search window size 81 x 81 (f) Image after applying second set of criteria

Table 1: Distribution of DR staging between two retina specialists for internal and external validation datasets

	No DR	Mild NPDR	Mod NPDR	Severe NPDR	PDR	95%
No DR	121	4	0	0	0	125 (8.2%)
Mild NPDR	8	16	6	0	0	30 (2.4%)
Mod NPDR	1	3	468	21	0	493 (32.2%)
Severe NPDR	0	0	11	130	37	178 (11.6%)
PDR	0	0	0	3	704	707 (46.1%)
Total	130	23	485	154	711	1533

	No DR	Mild NPDR	Mod NPDR	Severe NPDR	PDR	95%
No DR	538	10	0	0	0	548 (45.7%)
Mild NPDR	6	234	8	2	0	250 (19.2%)
Mod NPDR	1	0	329	5	2	337 (28.1%)
Severe NPDR	0	0	10	50	4	64 (5.3%)
PDR	0	0	0	0	21	21 (1.8%)
Total	545	24	347	57	27	1000

The percentage values in brackets indicate the proportion of cases under each stage of DR

Table 3: Performance of AI in comparison to Ground Truth for internal and external validation sets

Internal validation set		External validation set				
Sensitivity	90.37%	87.84%-92.52%	94.68%	92.12%-96.60%	91.67%	83.58%-96.58%
Specificity	91.03%	88.31%-93.29%	97.40%	96.01%-98.40%	92.92%	91.26%-94.36%
AUC	0.907	0.889-0.923	0.96	0.948-0.971	0.923	0.906-0.937
PPV	92.34%	90.22%-94.04%	95.34%	92.99%-96.93%	49.36%	43.84%-54.90%
NPV	88.75%	86.17%-90.90%	97.02%	95.62%-97.98%	99.33%	98.65%-99.67%
k	0.812	0.779-0.845	0.922	0.899-0.945	0.606	0.531-0.680

Any DR=detection Referable DR=detection Sight threatening DR=detection Sensitivity 99.71% 99.27% 99.92% 98.98% 98.30% 99.44% 97.55% 96.32% 98.46% Specificity 98.50% 94.71% 99.82% 94.84% 90.08% 97.75% 56.31% 82.35% 60.21% AUC 0.991 0.985 0.995 0.969 0.959 0.977 0.77 0.747 0.790 PPV 99.86% 99.44% 99.96% 99.42% 98.86% 99.70% 76.00% 74.34% 77.58%

NPV 97.06% 92.53% 98.87% 91.30% 86.16% 94.65% 94.20% 91.43% 96.10% k 0.975 0.956 0.995 0.922 0.890 0.954 0.572 0.532 0.612

External validation set

Any DR=Stage1,2,3,4; ReferableDR=Stage2,3,4; SightthreateningDR=Stage3and4

Fig2. (a)

Fig2. (b)

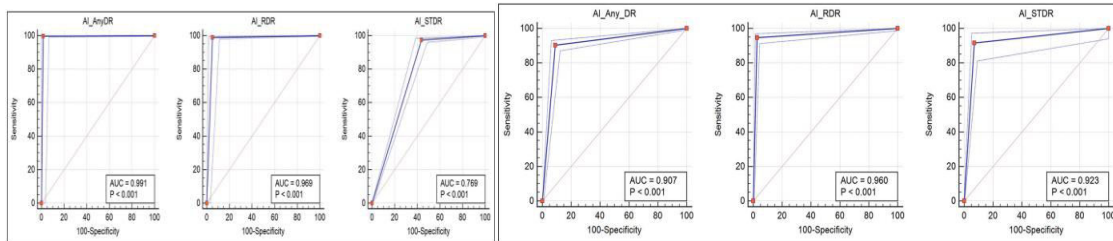


Fig2.(c)

Fig2. (d)

Table 5: Brief summary of previous studies and their comparison with our results

Dataset	sensitivity	Specificity
Any OR	30%	95%
Pram et al?	9%	87%
Gargeya and Leng	87.2%	90.7%
Abramoff et	99.7%	98.5%
Our study (India)	9.37%	91.00%
Referable DR	90.3% 97.5%	98.1% 93.4%
Gulshan et al	87%	98.5%
Ting of al"	96.1%	93.9%
Ramachandran et alin	90.5%	91.6%
Our study (India)	84.6%	79.7%
ODEMS (382)	96%	90%
Messidor 1 (1200)	98.96%	94.84%
1533 images		

Fig2.(e)

Authors	Algorithm	Year Training	Validation set set	Testing set	AUC	Sensitivity (%)	Specificity (%)	
Vandenberg et al	Inception-v3	2020-2025 (4055)	patient0-1000	EyePACS	0.890	95.00	90.00	
et al	Inception-v3	From	Thailand	1000	0.899	97.80	97.40	
Kemary et al	MobileNet	2018-2019	250	500	0.960	95.51	95.59	
Huang et al	InceptionV2	2020-2018 (173)	patient0-100	500	N/A	95.15	89.63	
Huang et al	DMNet	2020-2018 (173)	patient0-100	355	N/A	0.940-0.960-0.970	95.51	95.94
Singand	resNet	2020-2015 (1040)	1200	N/A	0.897	90.10	96.59-97.50	
Gorasia	VGG-16	(MEDI000)	7621-995	997	0.992	94.90	N/A	
Wu et al	SDU-net	2021-2023 (2018)	1000	N/A	1	N/A	95.40	
DePaul et	VGG-16	18884				97.81		
Li et al	Transfer Learning	2019-2020 (12)						

AI: Artificial intelligence; AUC: Area under curve; CNN: Convolutional neural network; DM: Diabetic macular edema; resNet: ResNet; Sample of Convolutional Neural Networks; DRD: Indian Diabetic Retinopathy Image Dataset; N/A: Not available.

Fig2.(f)

Fig. 2 Text Detection and Inpainting (a) Original image (b) Image after applying first set of criteria (c) Image after applying second set of criteria (d) Image mask (e) Inpainted image using patch size 5 x 5 and search window size 81 x 81 (f) Image after applying second set of criteria.

V. CONCLUSION

It impoverished nations with limited healthcare access, AI has the potential to revolutionize remote screening for diabetic retinopathy (DR), enabling rapid diagnosis without the need for trained specialists. The current status of DR screening highlights the importance of regular eye examinations, yet compliance remains low due to factors like inadequate insurance and access to resources. Telemedicine can enhance screening accessibility, while AI advancements improve efficiency and accuracy in diagnosing DR. AI systems like IDx-DR and EyeArt demonstrate high sensitivity and specificity, although challenges persist, such as dataset compatibility, classification standards, and the "black box" nature of AI decision-making. These systems also face limitations in clinical application, such as responsibility for diagnoses and data security. Overall, while AI-based diagnostic tools show promise in managing DR

and reducing blindness, ongoing refinements and robust validation are essential for their widespread implementation in diverse healthcare settings.

AI has the potential to revolutionize remote screening for diabetic retinopathy (DR) in impoverished nations with limited healthcare access, allowing for rapid diagnosis without the need for trained specialists. Despite the importance of regular eye examinations, compliance with DR screening remains low due to inadequate insurance and limited access to resources. Telemedicine can enhance accessibility, while advancements in AI improve the efficiency and accuracy of DR diagnoses, with systems like IDx-DR and EyeArt demonstrating high sensitivity and specificity. However, challenges such as dataset compatibility, classification standards, and the "black box" nature of AI decision-making, along with clinical application limitations regarding responsibility for diagnoses and data security, persist. Overall, while AI-based diagnostic tools hold promise for managing DR and reducing blindness, ongoing refinements and robust validation are essential for their widespread implementation across diverse healthcare settings.

Traditional machine learning methods, such as Support Vector Machines (SVM), Random Forests, and k-Nearest Neighbors (k-NN), have been employed for detecting diabetic retinopathy (DR) for years, relying on manually crafted features extracted from retinal images. Their performance heavily depends on the quality of the feature engineering process, making them less computationally demanding than deep convolutional networks (CNNs), but also requiring significant effort in feature extraction and selection. This manual process can be time-consuming and may not scale well with large or complex datasets. As a result, traditional methods often lag behind CNNs in terms of accuracy and sensitivity. While they offer greater interpretability and accessibility for smaller healthcare facilities, their lower effectiveness in DR detection limits their utility in large-scale screening programs, highlighting the need for more advanced approaches in managing this condition.

Traditional machine learning methods like Support Vector Machines (SVM), Random Forests, and k-Nearest Neighbors (k-NN) have long been used for diabetic retinopathy (DR) detection, relying on manually engineered features from retinal images. Although these methods are less computationally intensive than deep convolutional neural networks (CNNs), they demand significant effort in feature extraction and selection, making them less scalable for large or complex datasets. Consequently, their accuracy and sensitivity are lower than CNNs, limiting their effectiveness in large-scale DR screening programs. Despite their interpretability and accessibility, more advanced approaches are needed to manage DR more effectively.

Traditional machine learning methods like Support Vector Machines (SVM), Random Forests, and k-Nearest Neighbors (k-NN) have been widely applied in diabetic retinopathy (DR) detection, relying on manually engineered features from retinal images. While these methods are less computationally demanding compared to deep convolutional neural networks (CNNs), they require significant effort in feature extraction and selection, making them less scalable for large or complex datasets. As a result, their accuracy and sensitivity often fall short of CNNs, limiting their utility in large-scale DR screening programs. Although these traditional methods offer greater interpretability and accessibility for smaller healthcare settings, more advanced approaches like CNNs are increasingly necessary to manage DR detection more effectively.

REFERENCES

1. NCD Risk Factor Collaboration (NCD-RisC). Worldwide trends in diabetes since 1980: a pooled analysis of 751 population-based studies with 4.4 million participants. *Lancet* 2016;387:1513–1530. doi: 10.1016/S0140-6736(16)00618-8.
2. Ting DSW, Cheung GCM, Wong TY. Diabetic retinopathy: global prevalence, major risk factors, screening practices and public health challenges: a review. *Clin Exp Ophthalmol* 2016;44:260–277. doi: 10.1111/ceo.12696.
3. Yang W, Lu J, Weng J, Jia W, Ji L, Xiao J, et al. Prevalence of diabetes among men and women in China. *N Engl J Med* 2010;362:1090–1101. doi: 10.1056/NEJMoa0908292.
4. Wang M, Kou C, Bai W, Song Y, Liu X, Yu W, et al. Prevalence and correlates of suicidal ideation among college students: a mental health survey in Jilin Province, China. *J Affect Disord* 2019;246:166–173. doi: 10.1016/j.jad.2018.12.055
5. Li Y, Teng D, Shi X, Qin G, Qin Y, Quan H, et al. Prevalence of diabetes recorded in mainland China using 2018 diagnostic criteria from the American diabetes association: national cross sectional study. *BMJ* 2020;369:m997. doi: 10.1136/bmj.m997

6. BMJ 2020;369:m997. doi: 10.1136/bmj.m997. 8. Yau JWY, Rogers SL, Kawasaki R, Lamoureux EL, Kowalski JW, Bek T, et al. Global prevalence and major risk factors of diabetic retinopathy. *Diabetes Care* 2012;35:556–564. doi: 10.2337/dc11-1909.
7. Song P, Yu J, Chan KY, Theodoratou E, Rudan I. Prevalence, risk factors and burden of diabetic retinopathy in China: a systematic review and meta-analysis. *J Glob Health* 2018;8:010803. doi: 10.7189/jogh.08.010803
8. Wong TY, Klein R, Islam FMA, Cotch MF, Folsom AR, Klein BEK, et al. Diabetic retinopathy in a multi-ethnic cohort in the United States. *Am J Ophthalmol* 2006;141:446–455. doi: 10.1016/j.ajo.2005.08.063.
9. Tan GS, Cheung N, Simó R, Cheung GCM, Wong TY. Diabetic macular oedema. *Lancet Diabetes Endocrinol* 2016;5:143–155. doi: 10.1016/S2213-8587(16)30052-3
10. Preferred Practice Pattern® Guidelines. <https://www.aao.org/preferred-practice-pattern/diabetic-retinopathy-ppp>.



INTERNATIONAL
STANDARD
SERIAL
NUMBER
INDIA



INTERNATIONAL JOURNAL OF INNOVATIVE RESEARCH

IN SCIENCE | ENGINEERING | TECHNOLOGY

 9940 572 462  6381 907 438  ijirset@gmail.com



www.ijirset.com

Scan to save the contact details