



# International Journal of Innovative Research in Science Engineering and Technology (IJIRSET)

*(A Monthly, Peer Reviewed, Refereed, Scholarly Indexed, Open Access Journal)*



**Impact Factor: 8.524**

**Volume 14, Issue 1, January 2025**

# Rhino-Orbito-Cerebral Mucormycosis in COVID-19 Recovered Patients: An Observational Study

Rangrao M. Bhise<sup>1</sup>, Kiran H. Buge<sup>2</sup>, Sunita G. Nighute<sup>3</sup>

Associate Professor, Department of Physiology, DVVPF'S Medical College, Ahilyanagar, Ahmednagar,  
Maharashtra, India<sup>1</sup>

Professor, Department of Physiology, DVVPF'S Medical College, Ahilyanagar, Ahmednagar, Maharashtra, India<sup>2</sup>

Professor and HOD, Department of Physiology, DVVPF'S Medical College, Ahilyanagar, Ahmednagar,  
Maharashtra, India<sup>3</sup>

**ABSTRACT: Background:** India has reported a recent surge in Mucormycosis cases. Mucormycosis is a rare, life-threatening fungal infection having an increased incidence during this COVID-19 pandemic, especially in the second wave in India. Number of rhino-orbito-cerebral mucormycosis cases Post COVID-19 infection increased in Ahmednagar. **Aims and Objectives:** To study the early contact of mucormycosis infection after covid positive test. To study the relation of D-Dimer, C-Reactive protein, Sr. Ferritin, blood group and HbA1c to mucormycosis infection. To study the incidence of death rate in mucormycosis patient. **Materials and Methods:** This retrospective clinical analysis includes data collection of 30 patients from tertiary care hospital located in Ahmednagar district of Maharashtra, India from 1st May, 2021 to 31st August, 2021. All these were post COVID-19 patients presented after varying number of days postinfection and had undergone indoor treatment at various hospitals. **Results:** We had majority of the patients with blood group O+ 13 cases (43.33%), followed by A+ 9 cases (30%) and B+ 6 cases (20%). KOH mount showed Zygomycetes fungus in all specimens. Debridement was done in 22 patients (73.33%). There were 10 deaths in our study participants (33.33%). We observed a significant difference in Serum ferritin levels ( $p = 0.048$ ) and HbA1c levels ( $p = 0.017$ ) in patients who had died of Mucormycosis as compared to those who survived. **Conclusion:** Close correlation was observed between rhino-orbito-cerebral mucormycosis, diabetes mellitus and Serum Ferritin level in COVID-19 positive patients. Possible follow up and larger sample size will be needed to justify these results more.

**KEY WORDS:** Rhino Orbital Cerebral Mucormycosis, COVID-19 infection, Diabetes Mellitus, pandemic, SARS-CoV-2, Serum Ferritin.

## I. INTRODUCTION

The Severe Acute Respiratory Syndrome Coronavirus 2 (SARS-CoV-2) otherwise known as the novel Coronavirus (2019-nCoV) outbreak emerged in Wuhan, Hubei province of China in December 2019 has been dwindling the world since its declaration by the World Health Organization as a pandemic on 11th March 2020 [1].

Mucormycosis is a serious but rare fungal disease caused by fungi belonging to the family of Mucormycetes or Zygomycete[2]. It mostly occurring in immunocompromised patients. It is characterized by extensive angioinvasion that results in vessel thrombosis and subsequent necrosis. Pre-existing diseases such as diabetes mellitus, immunocompromised patients are more prone to mucormycosis. Systemic immune alterations of Covid-19 disease are increasingly being recognized in view of their impact on morbidity and mortality [3,4,5]. Recent case reports indicate an increased prevalence of mucormycosis in severe cases of Covid-19 after recovery [6,7]. Medical procedures and devices, such as contaminated air filters, oxygen tubing, humidifiers, infected wound dressings and tongue depressors have all been linked to nosocomial mucormycosis [8]. Duration of time for infection to occur is couple of days to weeks from covid recovery [9]. Clinical presentation can be diverse. The most commonly reported signs in the literature include nasal obstruction with noisy breathing, blood-stained nasal discharge, headache, facial cellulitis, orbital swelling, palatal ulceration or necrosis, and black necrotic eschar in the nasal cavities, severe pain and loss of vision [10,11,12]. Diagnosis can be done by KOH Mount, Magnetic Resonance Imaging (MRI), Endoscopy and

Culture report. Functional Endoscopic Sinus Surgery (FESS), conservative management by antifungal drugs and surgical debridement are the best treatment protocol [13]. Successful treatment of mucormycosis is dependent on four key principles: early diagnosis, treatment of underlying predisposing factors, surgical debridement of necrotic tissue, and administration of systemic Amphotericin B [14].

**Aims and objectives:**

1. To study the early contact of mucormycosis infection after covid positive test.
2. To study the relation of D-Dimer, C-Reactive protein, Sr. Ferritin, blood group and HbA1c to mucormycosis infection.
3. To study the incidence of death rate in mucormycosis patient

**II. MATERIAL AND METHODS****Study design:**

A retrospective cross-sectional observational study was conducted on total 30 patients admitted in a Tertiary care Hospitals, Ahmednagar to treat COVID-19 associated Mucormycosis from 1st May, 2021 to 31st August, 21. All total 30 patients were known cases of previous COVID-19 infection.

**Data collection:**

Routine blood investigations, ECG, chest Xray, CT scan and MRI of the face (including orbits) and brain were done (Fig 5). Sinusitis with mucosal thickening of ethmoidal and maxillary sinuses, facial swelling, sudden dental pain, headache, ophthalmoplegia (Fig 8), and orbital cellulitis (Fig.3) etc were few clinical features that the patients presented with in hospital. Ophthalmology reference was taken for those patients having orbital extension. Punch biopsy from the oral cavity especially the necrotic palatal part and/or collection of infected tissue/ nasal discharge is/are sent for (KOH test) (Fig.7), to screen for any fungal hyphae. Once Mucormycosis was confirmed, within 72 hours, surgery was performed as well (Fig 4). Post surgery, Amphotericin B therapy was started. Patient demographic details, COVID status, Co-morbidities, Clinical and treatment details, location of Mucor-mycosis and outcome were collected from case sheets of all patients admitted in Hospitals and the data was subsequently analysed. Standard informed consent to participate and publish were obtained from every patient. Diagnosis of Mucormycosis was based on European Confederation of Medical Mycology guidelines for diagnosing and managing mucormycosis.

**Inclusion criteria:**

All cases of mucor-mycosis after COVID - 19 infection was admitted in Hospitals for treatment are included in the study.

**Exclusion criteria:**

Any case of Mucormycosis without COVID - 19 positive was excluded from the study.

**Case definitions:**

A case of mucormycosis was defined as laboratory identification of Mucorales by histopathology, KOH mount, endoscopy, MRI SCAN and Lab report. Cases were considered COVID-19-associated if the patient received a positive reverse transcription-polymerase chain reaction or antigen test result for SARS-CoV-2 (the virus that causes COVID-19) during the 40 days preceding the mucormycosis diagnosis.

**Statistical Analysis:**

Data was collected and analysed using SPSS software. Quantitative data with normal distribution were expressed as mean +/- Standard deviation. Nominal data were given as a number(n) and percentage (%). P-value < 0.05 was considered as significant.

III. RESULTS

Table 1: Age & Gender distribution:

		sex		Total
		F	M	
Age group	< 40	1	2	3
	41-60	2	12	14
	61 - 80	3	10	13
Total		6	24	30

There were 24 males (80%) and 6 females (20%). Out of 30, 14 were from age group 41-60 years (46.67%), 13 were from age group 61-80 years (43.33%) and rest 3 were less than 40 years (10%). Age range was 30-80 years with mean age of 57.40 ± 12.45 years.

Table 2: Descriptive statistics of the study parameters:

	Minimum	Maximum	Mean	SD
Age (year)	30.0	80.0	57.40	12.45
Mucormycosis after COVID positive ( In days)	13.0	33.0	22.06	4.64
D-Dimer (ng/ml)	130.0	6819.0	1010.20	763.69
C -Reactive protein (mg/L)	15.0	267.0	64.26	46.58
Sr. Ferritin (ng/ml)	34.0	1739.0	461.16	356.76
Glycosylated Hb (%)	5.90	12.30	8.81	1.519

Table 3: Blood groups of the participants:

Blood Group	Frequency	Percent
A -	1	3.33%
A+	9	30.00%
AB +	1	3.33%
B+	6	20.00%
O+	13	43.33%
Total	30	100.00%

We had majority of the patients with blood group O+ 13 cases (43.33%), followed by A+ 9 cases (30%) and B+ 6 cases (20%).

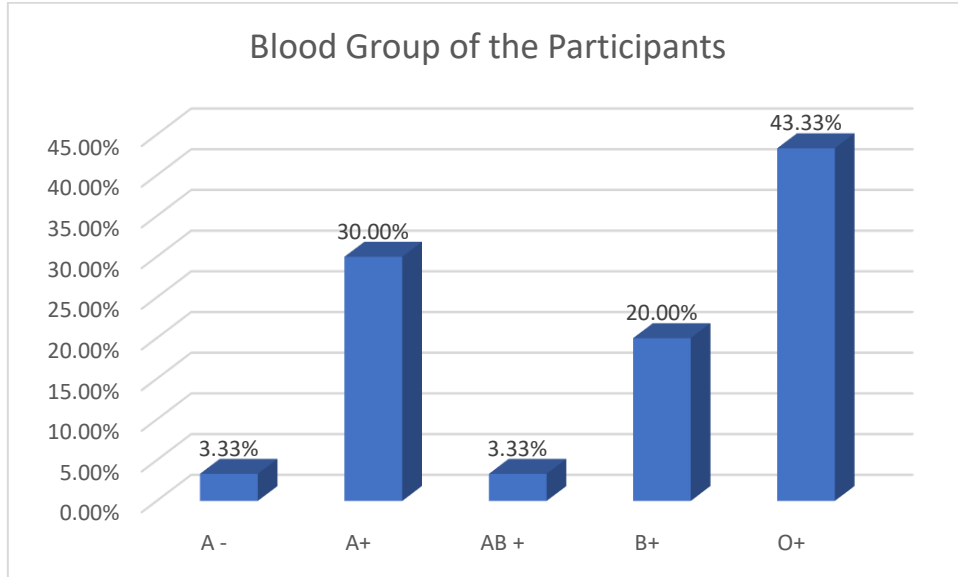


Fig1: Blood group of the participants

KOH mount showed Zygomycetes fungus in all specimens. Debridement was done in 22 patients (73.33%). There were 10 deaths in our study participants (33.33%).

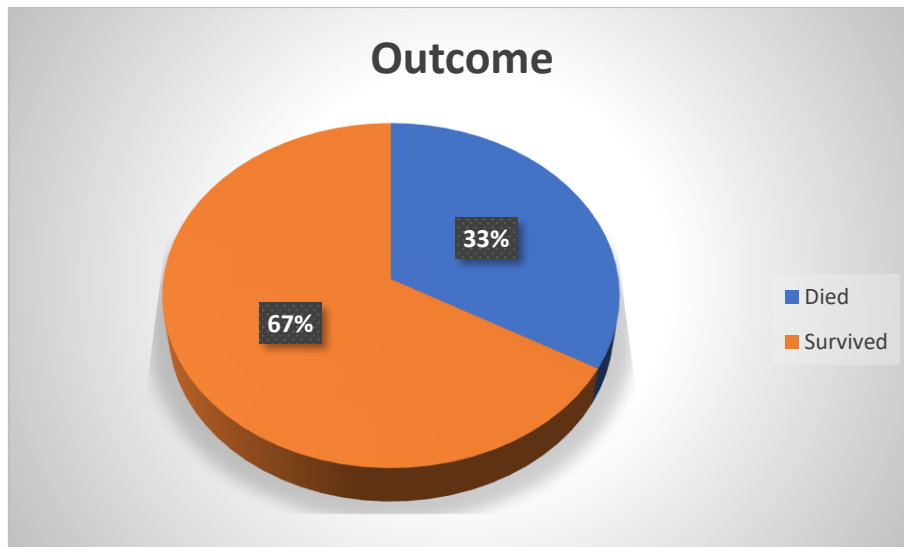


Fig 2: Outcome in our study participants

Table4: Difference between different study parameters in patients who Died:

	Death	Mean	SD	P Value
Mucormycosis after COVID positive ( in days)	Yes	22.40	6.13	0.78
	No	21.90	3.88	
D-Dimer (ng/ml)	Yes	1012.10	654.84	0.84
	No	979.25	446.12	
C -Reactive protein (mg/L)	Yes	73.40	32.84	0.46

	No	59.70	42.30	
Sr. Ferritin (ng/ml)	Yes	641.90	168.75	*0.048
	No	370.80	193.69	
Glycosylated Hb (%)	Yes	9.73	0.93	*0.017
	No	8.36	1.57	

We observed a significant difference in Serum ferritin levels ( $p = 0.048$ ) and HbA1c levels ( $p = 0.017$ ) in patients who had died of Mucormycosis as compared to those who survived. There was no any significant difference in number of days after Covid-positive, D-Dimer levels and C reactive protein levels ( $p > 0.05$ ). The Serum ferritin levels in patients who died were  $641.90 \pm 168.75$  ng/ml as compared to those who survived with levels of  $370.80 \pm 193.69$  ng/ml. The Glycosylated Hb was  $9.73 \pm 0.93$  in patients who died as compared to  $8.36 \pm 1.57$  in patients who survived. All 10 patients who died had undergone debridement (100%) and there was no any significant association between the deaths and blood group of the patients ( $p > 0.05$ ).

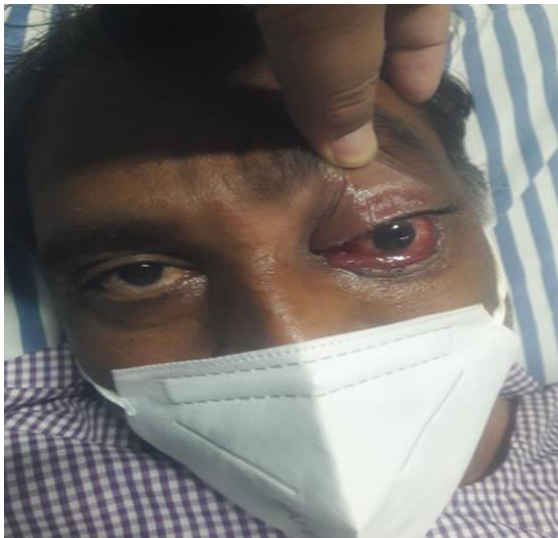

Figure 3: Orbital Mucormycosis

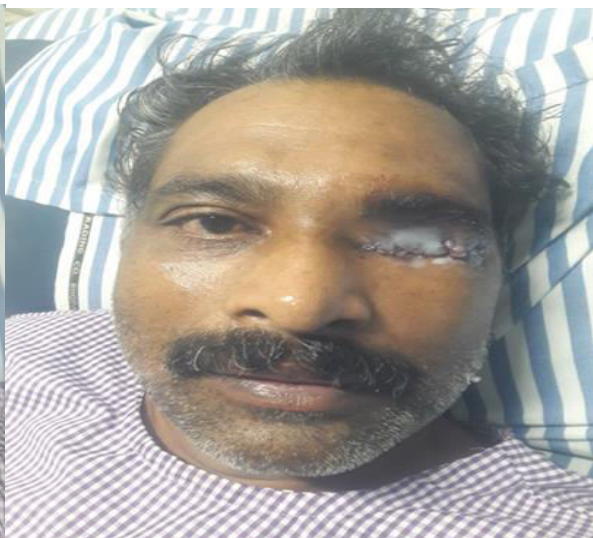

Figure 4: Debridement

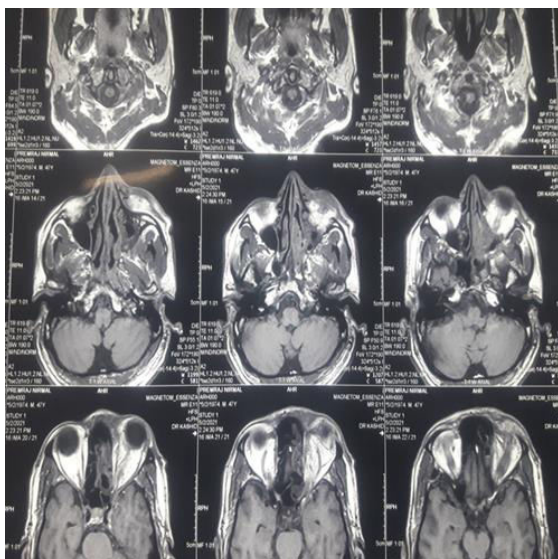


Figure 5: MRI Scan of Orbit

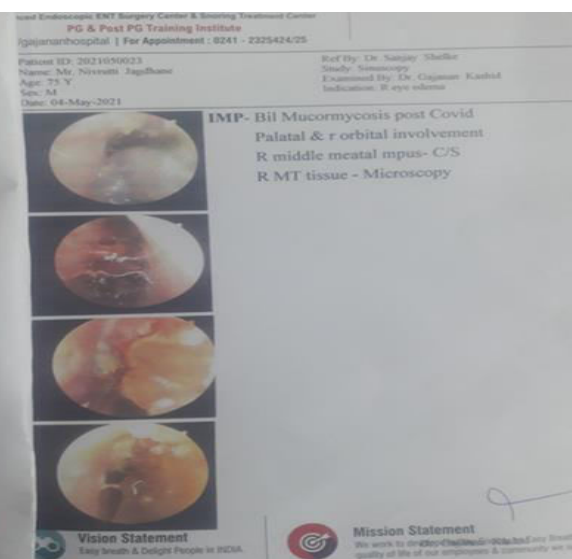


Figure 6: Endoscopy




Figure 7: KOH Test

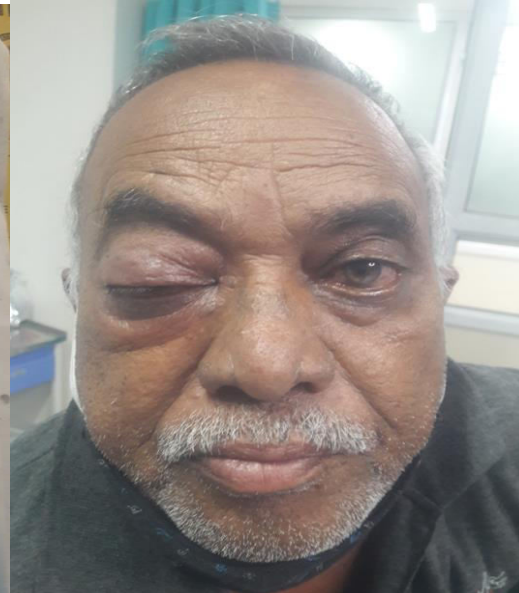

Figure 8: Ophthalmoplegia

#### IV. DISCUSSION

Mucormycosis is an aggressive and lethal infection caused by Zygomycetes [15,16]. The fungus has a likeliness to affect the nasal mucosa and mostly seen in immunosuppressive conditions like diabetes. Germination is seen in the nasal and paranasal sinuses ultimately involving the palate, orbit and brain causing death [17].

The prognosis is poor with about 33.33% being the overall mortality rate [18,19]. MRI scan is usually the first diagnostic tool to check the status of sinuses and to detect extra sinus spread [15]. A definitive diagnosis of mucormycosis as the causative species is achieved only by histological examination of the biopsy specimen and KOH mount. Due to the high mortality rate, need of early intervention by aggressive surgical debridement, systemic antifungal medications and management of underlying illness are much essential for a better rate of survival. A standard protocol of steroid administration for COVID-19 infection may need to be evaluated again and an emphasis on strict blood sugar control during and after COVID-19 infection should be done. Orbital exenteration can be done to reduce the disease burden and prevent the intracranial spread in cases where blindness is delayed even if having a clear radiological picture of involvement of the orbital cavity. In India, Rhino-orbital cerebral mucormycosis is more common compared to the Pulmonary form. It occurs more frequently in outside the ICU setting [20]. Ferritin, a key mediator contributor of cytokine storm and predictor of COVID severity [21,22]. Very high level of serum ferritin was found in almost all the patients as ferritin feeds and thrives the fungus, mucormycosis. Clinical findings along with MRI, lab tests, nasal endoscopy (FESS) has assessed the disease extension and an invasion pattern in an individual. Surgical debridement [23] is dependent on extension of an infection to get successful outcome from maxillary necrosis, orbital involvement, nasal crusting and intracranial involvement. debridement of necrotic tissue, enucleation and infra-temporal curettage were performed as a surgical procedure under prescribed necessary medications with time.

#### Limitations of our Study:

In this retrospective observational study, we could not compare various risk factors among COVID-associated Mucormycosis with Non- COVID patients to establish a causal association.

#### V. CONCLUSION

This clinical observational study includes few points to be considered in priority are Antifungal medications, surveillance of immuno-compromised status of diabetes mellitus in all patients, screening of COVID-19, early diagnosis of fungal co-infection, focus on triggering contributor factors and timely required treatment are a valuable means to control disease and its severe outcome. Potentials of developing rhino-orbito-cerebral mucormycosis in

patients having diabetes mellitus are more. A careful management plan for COVID-19 Disease can prevent rhino-orbital cerebral disease. Combined Medical and surgical management exhibited better outcomes.

#### Funding:

This work did not receive any grant from funding agencies in the public, commercial, or not-for-profit sectors.

#### Conflict of interest

There are no conflicts of interest to declare by any of the authors of this study.

#### ACKNOWLEDGEMENTS

We want to acknowledge Dr.Gautam Kale (Nerophysian), Dr.Gajanan Kashid (ENT Surgeon), Dr.Rane (Ophthalmologist), Dr.Gawali (Physician) for constant support and guidance.

#### REFERENCES

- [1] Kaneria MV, Baligeri K and Budhe A. Post COVID-19 mucormycosis: A case series. Asian Pacific Journal of Tropical Medicine, Vol. 14, No. 11, 2021, pp. 517-524.
- [2][https://www.who.int/india/emergenciesarchive/coronavirus-disease-\(covid-19\)/mucormycosis](https://www.who.int/india/emergenciesarchive/coronavirus-disease-(covid-19)/mucormycosis).
- [3] Song G, Liang G, Liu W (2020) Fungal co-infections associated with global COVID-19 pandemic: a clinical and diagnostic perspective from China. Mycopathologia 185(4):599–606. <https://doi.org/10.1007/s11046-020-00462-9>
- [4] Rawson TM, Moore LSP, Zhu N et al (2020) Bacterial and fungal coinfection in individuals with coronavirus: a rapid review to support COVID-19 antimicrobial prescribing. Clin Infect Dis 71(9):2459–2468. <https://doi.org/10.1093/cid/ciaa530>
- [5] Skiada A, Lass-Floerl C, Klimko N, Ibrahim A, Roilides E, Petrikos G (2018) Challenges in the diagnosis and treatment of mucormycosis. Med Mycol. 56(suppl\_1):93–101. <https://doi.org/10.1093/mmy/myx101>
- [6] Bassetti M, Kollef MH, Timsit JF (2020) Bacterial and fungal superinfections in critically ill patients with COVID-19. Intensive Care Med 46(11):2071–2074. <https://doi.org/10.1007/s00134-020-06219-8>
- [7] Hughes S, Troise O, Donaldson H, Mughal N, Moore LSP (2020) Bacterial and fungal coinfection among hospitalized patients with COVID-19: a retrospective cohort study in a UK secondary-care setting. Clin Microbiol Infect 26(10):1395–1399. <https://doi.org/10.1016/j.cmi.2020.06.025>
- [8] Petrikos G, Skiada A, Sambatakou H, Toskas A, Vaiopoulos G, Giannopoulou M, et al. Mucormycosis: Ten-year experience at a tertiary-care center in Greece. Eur J Clin Microbiol Infect Dis 2003;22:753-6.
- [9]. Anna Skiada et al. Review Epidemiology and Diagnosis of Mucormycosis: An Update J. Fungi 2020, 6, 265, pages 1-20
- [10]. Sen M, et al Mucor in a Viral Land: A Tale of Two Pathogens. Indian J Ophthalmol 2021; 69:244-52
- [11]. Sarkar S, Gokhale T, Choudhury SS, Deb AK. COVID-19 and orbital mucormycosis. Indian J Ophthalmol 2021;69:1002-4.
- [12] Balai E and Mummadi S. Rhino cerebral Mucormycosis: A Ten-Year Single Centre Case Series. Cureus, Vol.12, No. 11, pp. e11776.
- [13]. Aastha Maini Case report Sino-orbital mucormycosis in a COVID-19 patient: A case report International Journal of Surgery Case Reports 82 (2021) 105957
- [14] Karaaslan E. Anesthetic management of rhino-orbitocerebral mucormycosis; Focus on challenges. J Mycol Med. 2019;29(3):219–22.
- [15] Ferguson BJ — Mucormycosis of the nose and paranasal sinuses. Otolaryngol Clin North Am 2000; 33(2): 349-65.
- [16] Uçkay I, Chalandon Y, Sartoretti P, Rhoner P, Berney T, Hadaya K, et al — Invasive zygomycosis in transplant recipients. Clin Transplant 2007; 21(4): 577-82. doi: 10.1111/j.1399-0012.2007.00684.x
- [17] Mohindra S, Mohindra S, Gupta R, Bakshi J, Gupta SK — Rhinocerebral mucormycosis: the disease spectrum in 27 patients. Mycoses 2007; 50(4): 290-6. doi: 10.1111/j.1439-0507.2007.01364.x
- [18] Scheckenbach K, Cornely O, Hoffmann TK, Engers R, Bier H, Chaker A, et al — Emerging therapeutic options in fulminant invasive rhinocerebral mucormycosis. Auris Nasus Larynx 2010; 37(3): 322-8.
- [19] Jung SH, Kim SW, Park CS, Song CE, Cho JH, Lee JH, et al — Rhinocerebral mucormycosis: consideration of prognostic factors and treatment modality. Auris Nasus Larynx 2009; 36(27): 274-9.



- [20]. Patel A, Agarwal R, Rudramurthy SM, Shevkani M, XessI, Sharma R et al(2021) Multicenter epidemiologic study of coronavirus disease-associated mucormycosis, India. *Emerg Infect Dis* 27(9):2349–2359
- [21]. Bozkurt F, Tercan M, Patmano G, et al. (January 21, 2021) Can Ferritin Levels Predict the Severity of Illness in Patients With COVID-19?. *Cureus* 13(1): e12832.
- [22]. Banchini et al. RESEARCH ARTICLE Open Access Serum ferritin levels in inflammation: a retrospective comparative analysis between COVID-19 and emergency surgical non-COVID-19 patients *World Journal of Emergency Surgery* (2021) 16:9
- [23]. Sen M, et al Mucor in a Viral Land: A Tale of Two Pathogens. *Indian J Ophthalmol* 2021; 69:244-52



INTERNATIONAL  
STANDARD  
SERIAL  
NUMBER  
INDIA



# INTERNATIONAL JOURNAL OF INNOVATIVE RESEARCH

IN SCIENCE | ENGINEERING | TECHNOLOGY

 9940 572 462  6381 907 438  [ijirset@gmail.com](mailto:ijirset@gmail.com)



[www.ijirset.com](http://www.ijirset.com)

Scan to save the contact details